

Pediatric Distal Radius Fracture Malunions: Overview and Current Treatment Recommendations

Anil Akoon, C Liam Dwyer, Terri A Zachos* and Mark A Seeley

Department of Orthopaedic Surgery, Geisinger Medical Center, USA

Article Information

Received date: Sep 01, 2017

Accepted date: Sep 15, 2017

Published date: Sep 22, 2017

*Corresponding author

Terri A Zachos, Department of Orthopaedic Surgery, Geisinger Medical Center, USA, Tel: (517) 927-8865; Email: tazachos@geisinger.edu

Distributed under Creative Commons CC-BY 4.0

Keywords Distal radius reduction; Casting; Fracture reduction; Distal radius malunion; Pediatric distal radius surgery

Abstract

Pediatric distal radius fractures are common injuries. Most can be treated with closed reduction and immobilization. However, malunions can be sequelae of this injury pattern due to the risk of re-displacement after initial reduction, and clinical manifestations of these complications can be significant. In addition to malunion, the most concerning of these complications are nonunion and growth arrest. Addressing these concerns, particularly accurately determining which are clinically significant and may warrant surgical intervention, presents considerable clinical challenges. Acceptable parameters for flexion-extension angulation, radial-ulnar deviation and malrotation are controversial and vary based on age. Patients with functional impairment of motion, pain, and/or deformity due to malunion may be candidates for surgical reconstruction. Among these, the greatest improvements have been documented in patients with supination deficits, but the literature provides insufficient evidence to draw specific and definitive conclusions. The most commonly used reconstruction techniques are dorsal opening wedge osteotomy of the distal radius with volar bone grafting and ulnar shortening osteotomy, with release of the interosseous membrane. These are complex procedures that require assessment of 3-D anatomy, meticulous pre-operative planning and templating and continuous intra-operative reassessment. In addition, the risks of long-term sequelae, such as residual deformity resulting in impaired function, as well as an unacceptable cosmetic result, must be discussed with patients and their families at length when discussing the potential benefits, as well as complications, of operative versus non-operative management of malunions of the distal radius and forearm.

Background

Pediatric distal radius fractures are an increasingly common musculoskeletal injury and represent the most common forearm fracture in the pediatric population. Injuries to the distal radius represent 20 to 30% of all pediatric fractures and are more common in boys [1]. The incidence of malunion in pediatric distal radius fractures is inconsistently reported, due to the multiple variables associated with reporting these injuries and to the variable follow-up in this patient population. The incidence of growth arrest of the distal radius varies between 1 and 7% [2-4]. Nietosvaara et al [5] reported a 50% incidence of malunion in 109 consecutive children with displaced fractures of the distal radius treated with manipulation under anesthesia, despite documentation of anatomic primary reduction in 85% of these patients. Their logistic regression model predicted that marked initial displacement of the fracture (> 50% displacement or > 20% angulation) was an independent risk factor for complications and redisplacement of the fracture. An additional independent risk factor identified by this group was failure to obtain anatomic reduction of the fracture. This group found a 10% incidence of clinically significant growth arrest among the 20 patients (of their initial group of 109 patients) selected for long-term follow-up (up to two years). Clinically significant growth arrest refers to both complete arrest leading to shortening and/or angulation that results in impairment of function or partial arrest resulting in angulation. Both involve impairment of function, and this is the rationale for use of the descriptor, "clinically significant". It is important to emphasize that physeal arrest with malalignment or malrotation must not be confused with malunion.

Distal radius fractures often occur from an indirect injury related to a fall on an outstretched hand causing axial compression force that is transferred through the distal radius based on direction and rotation [6]. These fractures behave very differently from midshaft and proximal radius fractures secondary to the different deforming forces and the unique biomechanics of those areas.

Depending on the degree of force and location of transmission, this can result in either incomplete green stick or torus fractures or a complete fracture [7]. The fracture profile through the distal radius and the extent of the injury is related to the mechanism of injury, rotational position of the hand, degree of elbow flexion, and body mass [8]. Distal radius fractures may occur through the physis as an isolated injury, while others have concomitant distal ulnar fractures such as distal ulnar physeal injuries or distal radial ulnar joint dislocations also known as Galeazzi fractures.

Distal radius fractures are routinely treated with closed reduction and immobilization to obtain and maintain acceptable alignment. The definition of acceptable alignment is particularly controversial as anatomic reduction is not necessary for functional motion and strength [7]. Surgical indications for pediatric distal radius fractures include irreducible or unstable fractures, open fractures, soft tissue or neurovascular injuries precluding cast immobilization, those approaching skeletal maturity, Galeazzi fractures with an unstable distal radial ulnar joint, or floating elbow injuries [6,7]. Operative techniques include closed reduction with percutaneous pinning or nailing, or open reduction with pinning, nailing, or internal fixation with plates and screws. Despite closed reduction or even open reduction and immobilization, loss of reduction can occur resulting in malunions (Figure 1). Numerous factors have been correlated with loss of reduction including initial displacement greater than 50% or 100%, the accuracy of the initial reduction, an associated ulnar fracture, an isolated distal radius fracture, muscle atrophy, reduction of swelling from the initial injury, surgeon experience, fracture obliquity and the quality of casting [9]. Malunion is more likely following metaphyseal and diaphyseal injuries, when compared with physeal injuries: (53% [10,11] vs 14% [12,13]).

Cast wedging has been proposed as a method to potentially address the complication of redisplacement. It is reasonable to suggest that cast wedging is a reasonable alternative to address loss of reduction. However, this should be used in the context of the injury and understand that it is less effective the farther the fracture is out from the index time of injury. Cast wedging with physeal fractures

can be effective, but the fracture pattern and displacement need to be taken into account. Greater displacement will require more wedging, i.e. manipulation, which will put the growth plate at risk.

McLauchlan et al [14] reported that 7/33 patients (21.2%) in a prospective, randomized controlled trial including 68 children with completely displaced fractures of the metaphyses of the radius and ulna undergoing manipulation under anesthesia alone (vs percutaneous pinning) had to undergo a second procedure due to loss of initial reduction. This was a significantly higher incidence of loss of reduction when compared to patients undergoing operative fixation. These are among the clinical concerns cited in the need for consideration of operative management of these fractures.

Diagnosis

Distal radial malunions occur when bony healing results in unacceptable alignment with flexion-extension angulation, radial-ulnar deviation, or malrotation. Acceptable parameters vary based on age and are controversial. Complicating things further is the definition for loss reduction and angulation is not consistent throughout the literature. Adrian et al [15] defined angulation, as sufficient for inclusion in a randomized, controlled trial evaluating fractures of the distal forearm in children (AFIC), managed non-operatively versus with reduction and K-wire osteosynthesis, as follows: patients with fractures with angulation up to 30 degrees were included, with stipulations based on age (Table 1). Remodeling capacity decreases exponentially over time in pediatric forearm fractures [16].

The starting speed of remodeling depends on the initial displacement, allowing for increased remodeling potential in more displaced fractures [16], i.e., fractures with greater displacement at the time of injury should have the greatest biologic capacity for initial healing following the injury. Remodeling is anticipated in the young since the angular malunion is usually in the plane of motion of the joint, adjacent to the physis. Since 80% of the forearm growth comes from the distal radial physis there is great remodeling potential in this region [17]. Malunion in distal radius and/or ulna metaphyseal and physeal fractures may present significant clinical challenges [18-21]. Unfortunately, not all distal radius or ulnar fractures heal anatomically or remodel to an acceptable alignment. Specifically, rotational malunion is unlikely to remodel [22]. Angular malunion greater than 20 degrees will result in loss of forearm rotation at 1:2 ratio degree loss. These malunions may lead to a restriction in forearm rotation, possible ulnocarpal impingement and radiocarpal malalignment may lead to midcarpal instability.

Treatment

Prevention

Injuries to the distal forearm are primarily treated with closed reduction and immobilization. The principles of reduction generally require the use of traction to help gain length, recreation of the deformity to reduce tension through the periosteum, restoration of anatomic alignment and immobilization. A well molded splint

Table 1: Patients meeting criteria for diagnosis of angulation.

Age	Angulation
5-7 years	15-30 degrees
8-11 years	10-25 degrees

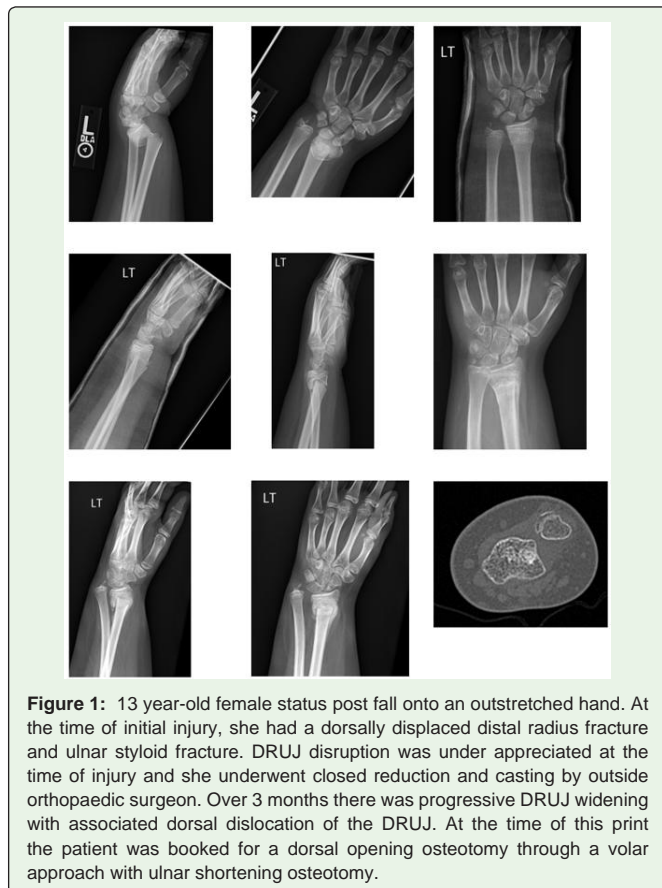


Figure 1: 13 year-old female status post fall onto an outstretched hand. At the time of initial injury, she had a dorsally displaced distal radius fracture and ulnar styloid fracture. DRUJ disruption was under appreciated at the time of injury and she underwent closed reduction and casting by outside orthopaedic surgeon. Over 3 months there was progressive DRUJ widening with associated dorsal dislocation of the DRUJ. At the time of this print the patient was booked for a dorsal opening osteotomy through a volar approach with ulnar shortening osteotomy.

is often used initially to allow for swelling followed by conversion to a cast once the swelling has resolved a few days after the injury. Overwrapping the splint as swelling decreases during this period is another method of safely ensuring proper immobilization during this time. This decreases the risk of vascular compromise associated with early application of a cast, while potentially also diminishing the risk of loss of reduction during the resolution of swelling in a cast applied soon after an injury. Obstacles to reduction include indirect impediment to reduction by the thick periosteum, commonly seen in younger children [11]. In addition, technical aspects associated with the environment may pose challenges to safe reduction of these fractures, as well as to maintaining reduction. These include inappropriate allocation of space to allow for appropriate access to the injured extremity, as well as use of pillows during and immediately following reduction and splinting.

A three-point mold is required for most distal radius fractures with pressure applied directly towards the apex of the fracture and counter pressure proximal and distal on the other side. An appropriate interosseous mold with pressure anterior and posteriorly over the interosseous membrane helps separate the bones and improve stability [6]. The cast index and three-point index are effective ways to assess cast quality [9,23]. It is important to cast well to prevent re-angulation. Studies have shown variable re-displacement rates ranging from 8%-91% with most noting that approximately one third of distal radius fractures can re-displace early after initial reduction [24,25]. If re-angulation is noted outside of acceptable parameters in 1 to 2 weeks after casting an additional closed reduction can be attempted or the patient can be treated operatively. Multiple reduction attempts increase the risk of iatrogenic injury, particularly compartment syndrome or physeal injury. If acceptable angulation is noted, the cast can be continued until there is a radiographic sign of healing which may be up to 6 to 8 weeks.

Non-operative management

Pediatric patients have a significant amount of growth and remodeling potential, particularly around the distal radial physis. Consequently, providers can accept greater degrees of deformity with fractures around the distal radius due to the body's increased ability to heal, particularly in younger patients, as 80% of radial growth comes from the distal physis [17]. Thus, it is important to assess each patient and fracture individually to determine the amount of displacement that can be tolerated, amount of growth left, how much remodeling is anticipated, how these factors will be affected by age and location, and if malalignment will affect motion, strength, function or patient satisfaction [2]. Multiple studies have attempted to quantify remodeling potential with radiographic calculable parameters with varying success [16]. Additionally, numerous studies have shown that despite the presence of radiographic malunion and even documented loss of 50 to 65 degrees of forearm rotation, children are adaptable and can adjust with altered kinematics, particularly shoulder abduction [22,26].

Surgical management

The most common indication for surgically addressing distal radius malunions are when they have significant motion loss, particularly greater than 60 degrees or significant discomfort at the DRUJ [17] and when there is limited remodeling potential. Surgical treatment

often entails osteotomies with internal fixation and bone grafting to correct malalignment (Figure 2). In general, management focuses on fixing the bone with the deformity, but optimizing forearm skeletal balance may require an ulnar shortening osteotomy. For best results, these procedures should be completed within one year of the initial injury [18]. While time from injury is a consideration, remaining growth potential and capacity for remodeling are, overall, significant factors in determining the potential for success with non-operative, vs operative management in this patient population. Indications for corrective osteotomy of the distal radius in patients with malunited fractures include functional loss of motion, pain and/or instability of the distal radioulnar joint and unacceptable cosmetic appearance of the arm. In the author's experience, the majority of severe cosmetic deformities are also associated with functional deficits. However, regardless of the reason for performing corrective osteotomy, patients must be warned of the potential for a surgical outcome with minimal improvement in range of motion and even reduced range of motion [27]. We therefore do not recommend surgical treatment of isolated cosmetic deformities.

Numerous techniques are available to address pediatric distal radial malunions based on the deformity and the presenting symptoms. Appropriate pre-operative planning with discussion of treatment goals and imaging studies including plain films and

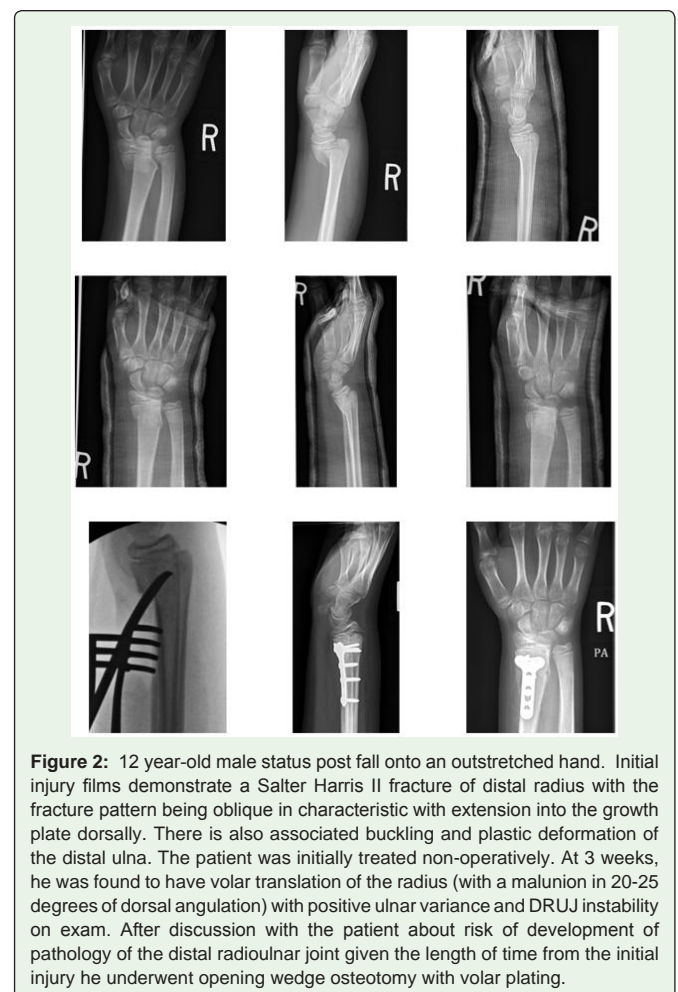


Figure 2: 12 year-old male status post fall onto an outstretched hand. Initial injury films demonstrate a Salter Harris II fracture of distal radius with the fracture pattern being oblique in characteristic with extension into the growth plate dorsally. There is also associated buckling and plastic deformation of the distal ulna. The patient was initially treated non-operatively. At 3 weeks, he was found to have volar translation of the radius (with a malunion in 20-25 degrees of dorsal angulation) with positive ulnar variance and DRUJ instability on exam. After discussion with the patient about risk of development of pathology of the distal radioulnar joint given the length of time from the initial injury he underwent opening wedge osteotomy with volar plating.

comparison to the contralateral extremity along with 3D CT scans with pre-operative templating are vital to successful outcomes. Supplemental planning with the use of 3D printing models and computer assistance osteotomies for guided cuts and hardware placement are also available. Two of the more commonly used techniques are a dorsal opening wedge osteotomy of the distal radius along with volar bone grafting and ulnar shortening osteotomy [28-30]. The volar locked plating systems lessen the risk of hardware irritation and/or extensor tendon disruption. The author's preferred technique is through a modified volar henry approach as is used in distal radius fractures. The FCR sheath is incised, and the pronator quadratus is mobilized. Sub-periosteal elevation allows for full visualization of the malunion and radius. A two-incision approach is generally not required and the osteotomy can be performed through this approach. Multiple orthogonal images are required to identify the maximum deformity. It is important to note whether there is malrotation and/or malangulation. Osteotomy in the plane of maximum deformity will allow for correction of both the coronal and sagittal imbalances. The plate is then aligned with the articular surface and fixed distally prior to making the osteotomy. Once the osteotomy is completed the joint will become anatomic. The intraoperative osteotomy plan should be confirmed with the preoperative plan and the bone should be cut. The plate is reduced to the bone proximally, which corrects the bone and joint malalignment. Almost always there is excessive bone that requires trimming and can be used as bone graft. If there are insufficient bone graft sites, the iliac crest or radial autograft can be harvested. It is imperative that motion be checked on the table and should be full without impingement. As in distal radius assessment, the radial articular alignment on AP and lateral images, ulnar variance on the AP image, and DRUJ alignment on the lateral image should be critically assessed. If there is residual deformity or motion restriction, then an ulnar osteotomy should be considered. If an ulnar osteotomy is required, this usually requires both rotational and angular correction. If both osteotomies are performed a strong consideration should be made to perform prophylactic forearm fasciotomies to lessen the risk for postoperative compartment syndrome.

Studies have shown that release of the interosseous membrane may be needed for correction of range of motion deficits in forearm malunion and does not cause weakness, instability of the DRUJ or synostosis. According to Nagy et al, [31] in their patients undergoing correction of forearm malunion, in those with primary complaints of loss of pronation, as well as those with primary complaints of loss of supination, release of the contracted interosseous membrane was frequently necessary in order to obtain correction. This may not be required for distal radius malunions but should be considered for more proximal reconstructions. Improvement in range of motion has been noted to be better for those with supination deficits than with pronation deficits and often overall range of motion may not be improved in the supination/pronation arc but pronation can be transferred to supination or *vice-versa* [22]. Complications associated with osteotomy include arthritic changes at the DRUJ, delayed union, infection, heterotopic ossification, refracture, neuromas or neurapraxias of the superficial radial sensory nerve, subluxation of the ulnar head, loss of motion and instability [27].

Conclusion

Pediatric distal radius fractures are common injuries. Most can be treated with closed reduction and immobilization. Some require operative fixation when satisfactory closed treatment cannot be completed. Malunions can be sequelae of this injury pattern due to the risk of re-displacement after initial reduction, presenting significant clinical challenges. The exact parameters of malunion are controversial but vary primarily based on flexion/extension angulation, radial/ulnar deviation and rotation and differ based on age, growth potential, and location among other factors. While many patients have radiographic malunions, few of these have loss of range of motion. Additionally, most pediatric patients with loss of range of motion do not have functional deficits due to their adaptability. Those that do suffer from functionally inhibiting loss of range of motion, pain or deformity due to malunion may require surgical treatment. The most commonly used techniques are dorsal opening wedge osteotomy of the distal radius along with volar bone grafting and ulnar shortening osteotomy along with release of the interosseous membrane. These are complex procedures that require assessment of 3-D anatomy, meticulous pre-operative planning and templating, and continuous intra-operative reassessment. In addition, the risks of long-term sequelae, such as residual deformity resulting in impaired function, as well as an unacceptable cosmetic result, must be discussed with patients and their families at length when discussing the potential benefits, as well as complications, of operative versus non-operative management of malunions of the distal radius and forearm. Specific discussions regarding the risk of malunions occurring subsequent to growth arrest, are of paramount importance particularly in younger patients. While the latter are less common, patients and their families must be aware of the potential need for further corrective procedures in the future if clinically significant deformities present during the short-, intermediate- and/or long-term follow-up periods, particular if the dominant extremity is involved.

References

1. Hove L, Brudvik C. Displaced paediatric fractures of the distal radius. Arch Orthop Trauma Surg. 2008; 128: 55-60.
2. Davis D, Green D. Forearm fractures in children. Pitfalls and complications. Clin Orthop. 1976; 120: 172-184.
3. Lee B, Esterhai J, Das M. Fractures of the distal radial epiphysis. Characteristics and surgical treatment of pre-mature, post-traumatic epiphyseal closure. Clin Orthop. 1984; 185: 90-96.
4. Cannata G, DeMaio F, Mancini F, Ippolito E. Physeal fractures of the radius and ulna: long-term prognosis. J Orthop Trauma. 2003; 17: 172-180.
5. Nietosvaara Y, Hasler C, Helenius I, Cundy P. Marked initial displacement predicts complications in physeal fractures of the distal radius: an analysis of fracture characteristics, primary treatment and complications in 109 patients. Acta Orthop. 2005; 76: 873-877.
6. Noonan K, Price C. Forearm and distal radius fractures in children. J Am Acad Orthop Surg. 1998; 6: 146-156.
7. Bae D. Pediatric distal radius and forearm fracture. J Hand Surg. 2008; 1911-1923.
8. Evans E. Fractures of the radius and ulna. J Bone Jt Surg Br. 1951; 33: 548-561.
9. Alemdaroglu K, Iltar S, Cimen O, Uysal M, Alagoz, E, Athhan D, et al. Risk Factors in Redisplacement of Distal Radial Fractures in Children. J Bone Jt Surg. 2008; 90: 1224-1230.
10. Daruwalla J. A study of radioulnar movements following fractures of the forearm in children. Clin Orthop Rel Res. 1979; 139: 114-120.

11. Mehlman C, Wall E. Diaphyseal Radius and Ulna Fractures. Rockwood Wilkins' Fract Child. 2015; 422-424.
12. DeCourtivron B. Spontaneous correction of the distal forearm fractures in children. Annu Meet Eur Pediatr Orthop Soc. 1995.
13. Schoenecker J, Bae D. Fractures of the Distal Radius and Ulna. Rockwood Wilkins' Fract Child. 2015; 366-369.
14. McLauchlan GJ, Cowan B, Annan IH, Robb JE. Management of completely displaced metaphyseal fractures of the distal radius in children. Bone Joint J. 2002; 84.
15. Adrian M, Wachtlin D, Kronfeld K, Sommerfeldt D, Wessel LM. A comparison of intervention and conservative treatment for angulated fractures of the distal forearm in children (AFIC): study protocol for a randomized controlled trial. Trials. 2015; 16: 437.
16. Jeroense K, America T, Witbreuk M, Sluijs J Van der. Malunion of distal radius fracture in children: Remodeling speed in 33 children with angular malunions of greater than or equal to 15 degrees. Acta Orthop. 2015; 233-237.
17. Tarr R, Garfinkel A, Sarmiento A. The effects of angular and rotational deformities of both bones of the forearm. An in vitro study. J Bone Jt Surg Am. 1984; 66: 65-70.
18. Mani G, Hui P, Cheng J. Translation of the radius as a predictor of outcome in distal radial fracture of children. J Bone Jt Surg Br. 1993; 75: 808-811.
19. Proctor M, Moore D, Paterson J. Redisplacement after manipulation of distal radial fractures in children. J Bone Jt Surg Br. 1993; 75: 453-454.
20. Gibbons C, Woods D. The management of isolated distal radius fractures in children. J Pediatr Orthop. 1994; 14: 207-210.
21. Wareham K, Johansen A, Stone M, Saunders J, Jones S, Lyons R. Seasonal variation in the incidence of wrist and forearm fractures, and its consequences. Injury. 2003; 34: 219-222.
22. Fuller D, McCullough C. Malunited fractures of the forearm in children. J Bone Jt Surg Br. 1982; 64: 364-367.
23. McQuinn A, Jaarsma R. Risk factors for redisplacement of pediatric distal forearm and distal radius fracture. J Pediatr Orthop. 2012; 32: 687-692.
24. Miller B, Widmann R, Base D, Snyder B, Waters, P. Cast immobilization versus percutaneous pin fixation of displaced distal radius fractures in children. J Pediatr Orthop. 2005; 490-494.
25. Zamzam M, Khoshhal K. Displaced fracture of the distal radius in children. J Bone Jt Surg Br. 2005; 87: 841-843.
26. Price C, Knapp D. Osteotomy for malunited forearm shaft fractures in children. J Pediatr Orthop. 2006; 26:193-196.
27. Trousdale R, Linscheid R. Operative treatment of malunited fractures of the forearm. J Bone Jt Surg Am. 1995; 77: 894-902.
28. Taleisnik J, Watson H. Midcarpal instability caused by malunited fractures of the distal radius. J Hand Surg Am. 1984; 9: 350-357.
29. Rogachefsky R, Ouellette E, Sun S, Applegate B. The use of tricortical cancellous bone graft in severely comminuted intra-articular fractures of the distal radius. J Hand Surg Am. 2006; 31: 623-632.
30. Fernandez D. Correction of post-traumatic wrist deformity in adults by osteotomy, bone-grafting, and internal fixation. J Bone Jt Surg Am. 1982; 64: 1164-1178.
31. Nagy L, Jankauskas L, Dumont C. Correction of forearm malunion guided by the preoperative complaint. Clin Orthop Rel Res. 2008; 466: 1419-1428.