

Advanced Stage Hepatoblastoma Case
Series Local Experience at King Fahad
Specialist Hospital - Dammam

Gamal Abbas*, Mansour Tawfeeq*, Awwad Nasralla*

Department of Surgery, King Fahad Specialist Hospital-Dammam, Saudi Arabia

Article Information

Received date: Dec 26, 2017

Accepted date: Jan 19, 2018

Published date: Jan 24, 2018

*Corresponding author

Gamal Abbas, Department of
Surgery, King Fahad Specialist
Hospital-Dammam, Saudi Arabia,
Tel: 096654711744;
Email: gemeabu@hotmail.com

Distributed under Creative Commons
CC-BY 4.0

Keywords Advance stage
hepatoblastoma; Chemotherapy; Surgery

Abstract

Hepatoblastoma is the most common hepatic tumor in children, it accounts for 1% of pediatric malignant tumor [1]. The treatment modalities include surgery and neoadjuvant or adjuvant chemotherapy. The advancement in the field of chemotherapy led to improved survival [2,3]. Herein, we report 4 cases of children with advanced stage hepatoblastoma who were successfully treated with combination of chemotherapy and surgery with an excellent outcome.

Background

Hepatoblastoma is the most common hepatic tumor in children, it accounts for 1% of pediatric malignant tumor [1]. The treatment modalities include surgery and neoadjuvant or adjuvant chemotherapy. The advancement in the field of chemotherapy led to improved survival [2,3]. Here in, we report 4 cases of children with advanced stage heptaoblastoma who were successfully treated with combination of chemotherapy and surgery at King Fahad Specialist Hospital in Dammam in the period between 2012 and 2015.

Case 1

Two-year-old girl presented with painless abdominal distension. On presentation, her vital signs were within normal, not jaundiced, with no dysmorphic features. On examination, she was found to have hepatomegaly, the liver edge was palpable 10 cm below the costal margin. Her laboratory investigation including Liver function test (LFT) were normal except Alpha fetoprotein (AFP) which was high (71216 ng/ml). Computed tomography (CT) of the chest, abdomen, and pelvis showed a right liver mass measuring 11 X 8 X 8 cm with compression of Inferior vena cava (IVC) and Portal vein (PV). The right hepatic vein was displaced while the left hepatic vein was not. In addition, she had bilateral pulmonary metastasis (high risk PRETEXT stage IV). The tru-cut biopsy of the liver mass confirmed the diagnosis of hepatoblastoma. She received 5 cycles of neoadjuvant chemotherapy (cisplatin and doxorubicin), after which the tumor size reduced and the pulmonary metastasis disappeared (POST-TEXT stage II). Then, the child underwent right hepatic lobectomy. The histopathological examination revealed hepatoblastoma, mixed fetal and mesenchymal type with partial chemotherapy response and negative margins. After the surgery, AFP dropped to normal level (0.37ng/ml). Five years following the surgery, the patient had no tumor recurrence.

Case 2

Seventeen-month-old boy referred to our hospital with a history of repeated attacks of abdominal pain. Upon examination, his vital signs were normal. He was not jaundiced, nor pale, no dysmorphic features were appreciated. During the abdominal examination, enlargement of the liver was appreciated reaching 3 cm below the costal margin. His laboratory investigations were normal except elevated AFP (38362 ng/ml). Computed tomography (CT) of the chest, abdomen and pelvis showed large exophytic liver mass (7.6 X 6.7 X 6.5 cm, transverse and anterior-posterior dimension respectively) in segments III and IV bulging into segment V displacing the following structures the infrahepatic segment of IVC, the head of pancreas, and the gallbladder, encasing the left portal vein branches (PRETEXT stage III) with no distant metastasis (Figure 1). The diagnosis of hepatoblastoma was confirmed by tru-cut biopsy. The patient received three cycles of chemotherapy (cisplatin and doxorubicin). Post- chemotherapy the liver lesion showed significant interval regression, involving segment IV and III (POSTTEXT stage II) (Figure 2). Left hepatic lobectomy was done uneventfully. Histopathological analysis showed microscopic foci of residual hepatoblastoma, fetal type, the surgical margins were free of the tumor. Three years after the surgery, AFP was normal (3.75ng/ml) and the CT showed no recurrence nor metastasis.

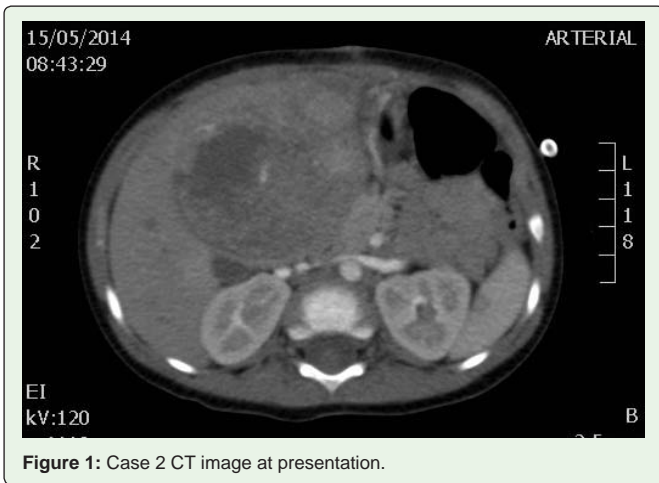


Figure 1: Case 2 CT image at presentation.

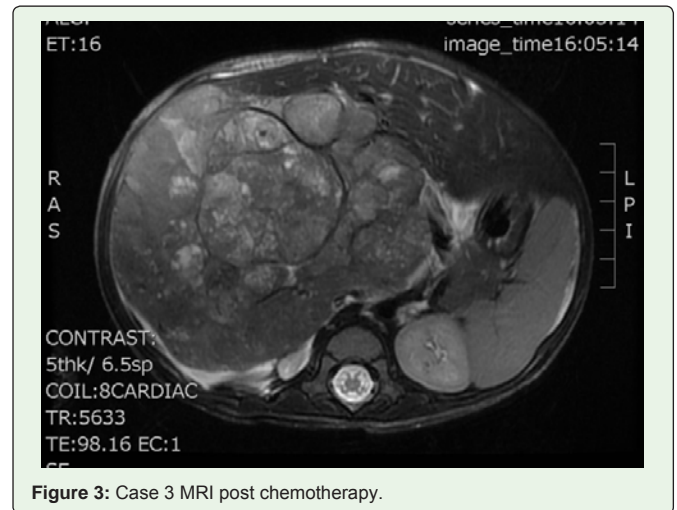

Figure 3: Case 3 MRI post chemotherapy.

Case 3

One-year-old boy presented with abdominal distension and weight loss. His vital signs on presentation were within normal. He was pale, not jaundiced. On examination, he was found to have hepatomegaly, liver reaching 10 cm below the costal margin. Magnetic resonance imaging (MRI) of the chest, abdomen and pelvis showed multiple heterogeneously enhancing hepatic lesions in both hepatic lobes with the largest one seen in the right and caudate lobes measuring about 11.3 X 9.4 X 12 cm. The right hepatic vein was obliterated by the mass and similarly the intrahepatic IVC is obliterated. The right portal vein was displaced inferiorly and the mass is compressing the right kidney and displacing it infero-medially and displacing the pancreatic head to the left side with loss of the fat plane between them. However, the sagittal images showed no evidence of invasion of the anterior cortex of the right kidney. There are few lung nodules mainly right-sided, the largest one measuring about 0.9 X 0.7 cm in the right upper lobe, similar sub-pleural nodules were seen at the left lung as well which were likely metastatic lesions (high risk hepatoplastoma, PRETEXT stage IV). Laboratory investigations revealed low hemoglobin (8.7) and elevated AFP (1867832 ng/ml). The Histopathological result of the tru-cut biopsy was fetal type hepatoblastoma. The boy received five cycles of chemotherapy (cisplatin and doxorubicin) with significant reduction in the lesion size on MRI (POSTTEXT stage III) (Figure 3). Right trisegmentectomy was performed uneventfully. Histopathological examination of the specimen showed hepatoblastoma, mixed

epithelial and mesenchymal type with negative margin. In addition, a left liver nodule which was biopsied during the resection was negative for malignancy. Latest CT on follow up showed no tumor recurrence or distant metastatic lesions. Additionally, the recent AFP dropped to 0.74ng/ml. The child is disease free six years after the diagnosis.

Case 4

Twenty-month-old boy had an abdominal mass with elevated AFP (67000 ng/ml). Computed Tomography (CT) of the chest, abdomen, and pelvis revealed a large well defined heterogeneous liver mass measured 11 X 11 X 8 cm in the right lobe displacing hepatic veins and portal vein, compressing intrahepatic IVC with a right subpleural nodule (high risk PRETEXT stage III). A tru-cut liver biopsy showed a fetal type hepatoblastoma. The patient received 3 cycles of chemotherapy (cysplatine and doxorubicin). After which the AFP decreased (15 ng/ml) and CT demonstrated partial response to chemotherapy with unrespectable liver tumor. Another cycle of chemotherapy was given which made the tumor amenable resection to surgery (POSTTEXT stage II) (Figure 4). Accordingly, extended right trisegmentectomy was performed. Then, the patient developed

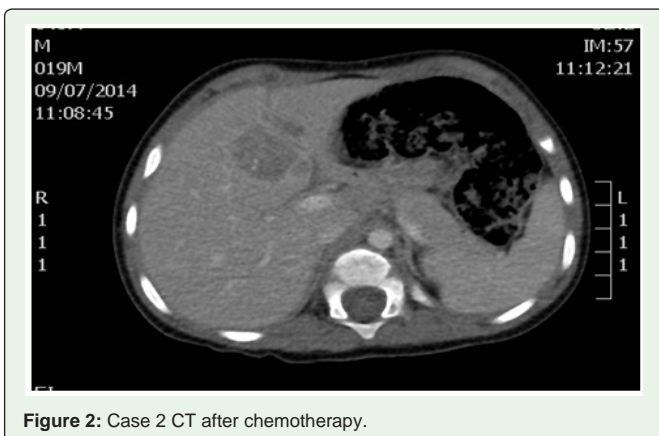

Figure 2: Case 2 CT after chemotherapy.

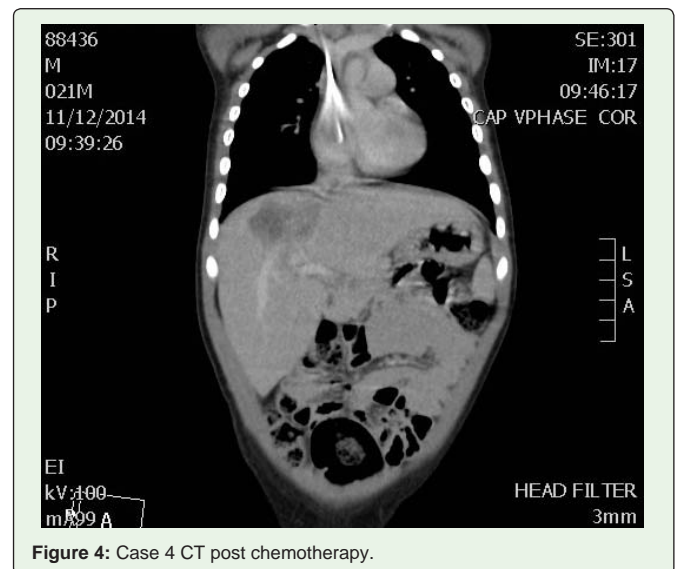


Figure 4: Case 4 CT post chemotherapy.

postoperative ascites which was treated conservatively. Three years after, the boy is doing well with no disease recurrence.

Discussion

Malignant tumor of the liver is uncommon in the pediatric age group; hepatoblastoma is the most frequent hepatic tumor in children [4]. The usual presentation of hepatoblastoma is an upper quadrant abdominal mass, with or without symptoms such as abdominal pain, which was the common presentation of all our patients. Majority of patients present between the age of 2-5 years, with 69% of patient present by the end of the 2 year of live and 90% develop by the end of 5 years with a definite male predominance [5]. The only chance for long-term cure is complete resection of primary tumor. Administration of cisplatin based chemotherapy in 1980 it resulted in reduction of intraoperative death due to bleeding and improved overall survival from 30 % reaching up to 70 % by 1990, that had increased further to about 80% in the most recent trials [6,7,8] . The timing of administration of the chemotherapy varies between the two common study groups. The International Childhood Liver Tumors Strategy Group (SIOPEL) suggested administering the chemotherapy prior to surgery. However, the Children's Oncology Group (COG), the Japanese and the German groups, suggested to administer the chemotherapy after the resection of the tumor [8,9]. In this case series, the patients presented with advanced stage hepatoblastoma stage III and IV for which they received neoadjuvant chemotherapy (cisplatin and doxorubicin) to shrink the size of the tumor. Computed tomography was repeated for all the patients after the chemotherapy which showed the reduction of the tumor size and disappearance of the metastatic lesions in children with metastatic disease except one patient who had MRI. Then, they underwent resection of the tumor in the form of hepatectomy or trisegmentectomy. There was no bile leak, no bleeding, nor infection. No tumor recurrence or metastatic spread detected during the follow up CT that was done 2 to 3 years after the surgery. In addition, the AFP dropped to normal levels. These complex liver resections without major intraoperative or postoperative complications became more feasible because of more anatomical delineation obtained from images, in addition to the use of neoadjuvant chemotherapy [10]. This is obvious in all our cases especially the third patient who presented with advanced stage (PRETEXT stage IV), but was managed successfully without transplantation. This emphasizes the importance of the multidisciplinary approach for these patients with advanced hepatoblastoma. Excellent survival (93%) was obtained with aggressive resection in children with advanced hepatoblastoma stage

III and IV. Operative exploration is required sometimes to ultimately determine whether the tumor is amenable to resection or requires liver transplantation [11].

Conclusion

In cases of advanced stage hepatoblastoma, high standard surgical technique after administration of cisplatin based neoadjuvant chemotherapy obviously lead to excellent outcome and with improved overall survival.

References

1. Tannuri AC, Cristofani LM, Teixeira RA, OdoneFilho V, Tannuri U. New concepts and outcomes for children with hepatoblastoma based on the experience of a tertiary center over the last 21 years. *Clinics (Sao Paulo)*. 2015; 70: 387-392.
2. Allan BJ, Parikh PP, Diaz S, Perez EA, Neville HL, Sola JE. Predictors of survival and incidence of hepatoblastoma in the paediatric population. *HPB (Oxford)*. 2013; 15: 741-746.
3. Meyers RL, Czauderna P, Otte JB. Surgical treatment of hepatoblastoma. *Pediatr Blood Cancer*. 2012; 59: 800-808.
4. Lautz TB, Ben-Ami T, Tantemsapya N, Gosiengfiao Y, Superina RA. Successful nontransplant resection of POST-TEXT III and IV hepatoblastoma. *Cancer*. 2011; 117: 1976-1983.
5. Ashcraft KW, Holcomb George W, Murphy JP, Ostlie DJ. *Ashcraft's pediatric surgery Philadelphia: Saunders/Elsevier*. 2010.
6. Zsíros J, Maibach R, Shafford E, Brugieres L, Brock P, Czauderna P, et al. Successful treatment of childhood high-risk hepatoblastoma with dose-intensive multiagent chemotherapy and surgery: final results of the SIOPEL-3HR study. *J Clin Oncol*. 2010; 28: 2584-2590.
7. Perilongo G, Maibach R, Shafford E, Brugieres L, Brock P, Morland B, et al. Cisplatin versus cisplatin plus doxorubicin for standard-risk hepatoblastoma. *N Engl J Med*. 2009; 361: 1662-1670.
8. Horton JD, Lee S, Brown SR, Bader J, Meier DE. Survival trends in children with hepatoblastoma. *Pediatr Surg Int*. 2009; 25: 407-412.
9. Fuchs J, Rydzynski J, Von Schweinitz D, Bode U, Hecker H, Weinel P, et al. Pretreatment prognostic factors and treatment results in children with hepatoblastoma: a report from the German Cooperative Pediatric Liver Tumor Study HB 94. *Cancer*. 2002; 95: 172-182.
10. Herzog CE, Andrassy RJ, Eftekhari F. Childhood cancers: hepatoblastoma. *Oncologist*. 2000; 5: 445-453.
11. Ortega JA, Krailo MD, Haas JE, King DR, Ablin AR, Quinn JJ, et al. Effective treatment of unresectable or metastatic hepatoblastoma with cisplatin and continuous infusion doxorubicin chemotherapy: a report from the Childrens Cancer Study Group. *J ClinOncol*. 1991; 9: 2167-2176.