

Rapunzel Syndrome Trichobezoar in a
4-Year Old Boy: An Unusual Case Report
with Review of LiteratureAli E Joda^{1,2*}, Waad M Salih², Riyadh M Al-Nassrawi³ and Nawzat H²¹Department of surgery, Mustansiriyah University, Iraq²Department of pediatric surgery, Central Child Teaching Hospital, Iraq³Department of Pediatric radiologist, Central Child Teaching Hospital, Iraq

Article Information

Received date: Jan 08, 2018

Accepted date: Jan 19, 2018

Published date: Jan 24, 2018

*Corresponding author

Ali E Joda, Department of surgery,
Mustansiriyah University, Iraq,
Tel: +964 772 546 5090;
Email: ali.egab.joda@gmail.com

Distributed under Creative Commons
CC-BY 4.0

Keywords Trichobezoar; Trichophagia;
Rapunzel syndrome; Children

Abstract

Background: The term bezoar refers to swallowed material (either food or foreign body) that fails to clear from the stomach and accumulates into masses of concretions. It can be classified into many types: phytobezoar (vegetable); trichobezoar (hair); lactobezoar (milk/curd), pills (pharmacobezoar) and miscellaneous (wool, cotton, sand, paper, etc.). Usually, the trichobezoar is confined within the stomach but in some cases extends through the pylorus into duodenum & various lengths of the intestine & this is called "Rapunzel Syndrome".

Method: we presented a case of 4-year-old boy with gastric trichobezoar and extension of its tail to the duodenum & rest of small bowel. The purpose of reporting this case is the rare occurrence of such condition discussing the presentation, diagnostic modalities & the ideal option of surgical treatment.

Result: The patient was presented with recurrent attacks of acute epigastric pain, vomiting and loss of appetite. Abdominal examination revealed mild abdominal distention with a soft, non-tender mass in the epigastric region. The mass was movable with respiration and it was possible to get above it. Abdominal sonography revealed a large a heterogeneous mass within the stomach, a diagnosis of gastric trichobezoar was suggested and confirmed by CT scan with oral contrast which revealed a large filling defect in the stomach and non-enhancing intraluminal gastric mass. During laparotomy, a stomach-casted mass of trichobezoar was delivered through gastrotomy with uneventful postoperative recovery and no complications were recorded.

Conclusion: Trichobezoar or Rapunzel syndrome in children is rare and there are many factors associated with trichophagia. The clinical Presentation is usually late, may present as an emergency that surgeons should be prepared to deal with. It can be diagnosed by ultrasound, contrast films, CT scan or endoscopy. In spite of several therapeutic options used, laparotomy is still considering the treatment of choice.

Introduction

The word bezoar is derived from the Arabic "badzehr" or from the Persian "padzahr," which literally means "antidote". The Andalusian physician Ibn Zuhr (d. 1161), known in the West as Avenzoar, is thought to have made the earliest description of bezoar stones as medicinal items because stones obtained from the stomach or intestines of animals were thought to have medicinal properties [1]. Today, the term bezoar refers to swallowed material (either food or foreign body) that fails to clear from the stomach and accumulates into masses of concretions [1,2]. Bezoars can be classified into many types: phytobezoar (vegetable); trichobezoar (hair); lactobezoar (milk/curd), pills (pharmacobezoar) and miscellaneous (wool, cotton, sand, paper, etc) [3,4]. Although the prevalence of bezoars in humans is low, if untreated, have associated mortality rates as high as 30% primarily because of gastrointestinal bleeding, destruction or perforation [4]. The most frequent type of bezoar in children and teenage girls is trichobezoars, while phytobezoars are more often found in adult [4]. Bezoar are usually found in the stomach, but they may also be found in the duodenum and other parts of the intestine [3,5].

The pathogenesis of bezoars is not consensual. Human hair is resistant to digestion as well as peristalsis & it is believed that the smooth surface of hair does not allow for its propagation through peristalsis, being trapped between the mucosal folds of the stomach [6]. Over a period, continuous ingestion of hair leads to its impaction together with mucus and food, causing the formation of a trichobezoar. However, the stomach of normal individuals is able to clear even large foreign bodies in up to 80 to 90% of the cases which may imply that bezoar formation occurs in the presence of altered gastric anatomy or physiology (e.g. after gastric surgery) or continued ingestion of the offending substance in case of underlying psychiatric problem, such as trichotillomania (the irresistible urge to pull one's own hair) and swallow it (trichophagia) [7,8].

Trichobezoar is a rare condition almost exclusively seen in young females [9,10]. Usually, the trichobezoar is confined within the stomach but in some cases extends through the pylorus into jejunum & various lengths of the intestine & this is called "Rapunzel Syndrome", for its resemblance

to a tail [11]. Vaughan described the syndrome first in 1968 and since then thirteen more cases have been reported in the literature [12,13]. The name “Rapunzel” syndrome comes from the German fairy tale in the collection assembled by the Brothers Grimm (a 12-year-old princess who was prisoned into a tower with neither stairs nor doors by a witch, the prince then rescues her by climbing up the tower’s walls with the help of Rapunzel’s long tresses) [14].

In the early stage, most trichobezoars may not be recognized due to their nonspecific presentation or even lack of symptoms, it continues to grow in size and weight due to the continued ingestion of hair and may present with signs and symptoms of acute abdomen and intestinal obstruction. These include abdominal pain, nausea, bilious vomiting, hematemesis, anorexia, early satiety, weakness, weight loss and palpable abdominal mass, depending on the degree of obstruction [3,4]. This condition if untreated has increased risk of severe complications, such as gastric mucosal erosion, ulceration and even perforation of the stomach or the small intestine. In addition, intussusception, obstructive jaundice, protein-losing enteropathy, pancreatitis and even death have been reported as complications of (unrecognized) trichobezoar in the literature [15-19]. The diagnosis of trichobezoars is based on imaging study. Although ultrasonography is effective in detecting an epigastric mass, CT-scan is more accurate in revealing a characteristic bezoar image and allowing the identification of the presence of additional gastrointestinal bezoars. The definite diagnosis is established by endoscopy [3,20].

We herein report a case of 4-year-old boy diagnosed with gastric trichobezoar. Evaluation of causes, presentation and the therapeutic options was discussed based on a review of the published literature.

Case Report

A 4-year-old boy was brought to the emergency department of the Central Child Teaching Hospital in Baghdad with a three-day history of crampy abdominal pain, nausea, and non-bilious vomiting. He had been recently developed recurrent attacks of acute epigastric pain and the child had been noted to be losing appetite but this was

never investigated. Initial Family history was unremarkable and. The parents denied any abnormal feeding habit with no other medical or surgical history.

On examination the child was well built, no sign of malnutrition was apparent and there was no alopecia. Abdominal examination revealed mild abdominal distention with a soft, non-tender mass in the epigastric region. The mass was movable with respiration and it was possible to get above it, the bowel sounds was normal. Laboratory values including a full blood count, urea and electrolytes did not show any abnormalities.

A Plain abdominal X-rays in the upright view revealed an abnormal air shadow in the region of stomach. abdominal sonography revealed a large a heterogeneous mass within the stomach and a Computed Tomographic (CT) scan with oral contrast was obtained, revealing a large filling defect in the stomach and non-enhancing intraluminal gastric mass suggestive of a trichobezoar (Figure 1), another retrospective detailed history taking from the boy revealed a long history of hair and fur eating mostly from soft toys and there was evidence of subnormal mentality & psychological problems related to family. A nasogastric tube was inserted which drained 50 ml of gastric secretion over 10 h.

Laparotomy was planned and was carried out through an upper midline incision. The grossly dilated stomach was easily visualized (Figure 2). An anterior gastrotomy was performed through a 6-cm longitudinal incision (Figure 3) and the mass of trichobezoar was delivered from the stomach (Figure 4). It was J-shaped (or stomach-casted), foul-smelling black bunch of hairs 20×8 cm and about 850 g. The tail of this mother bezoar was seen to have gone through the duodenum to jejunum and there was also a daughter bezoar of 5×3 cm in size and about 50 g in the jejunum about 40 cm away from the mother bezoar and attached to it by a continuous threads of hair, it was pulled through the same gastrotomy (Figure 5). The trichobezoar was found to contain human hair and synthetic fibres. There was moderate gastritis along the lesser curve but no apparent gastric ulceration. The gastrotomy was closed in two layers with absorbable sutures, no drains were left and the abdominal fascia and skin were closed.

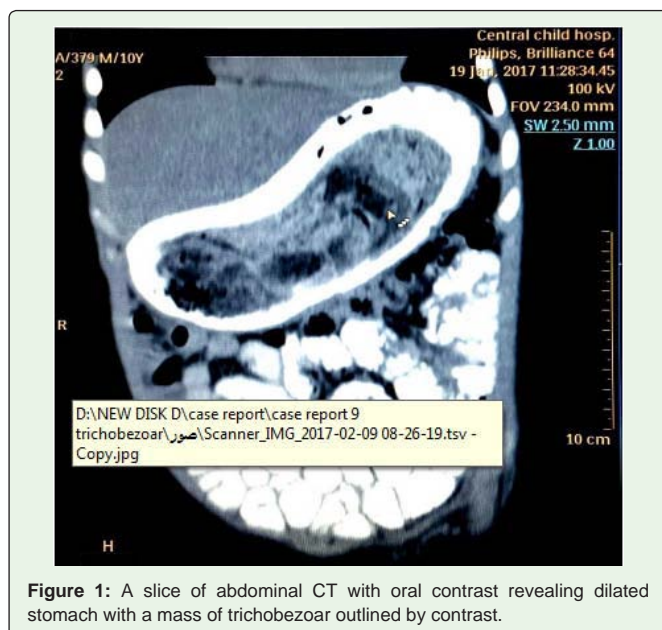


Figure 1: A slice of abdominal CT with oral contrast revealing dilated stomach with a mass of trichobezoar outlined by contrast.

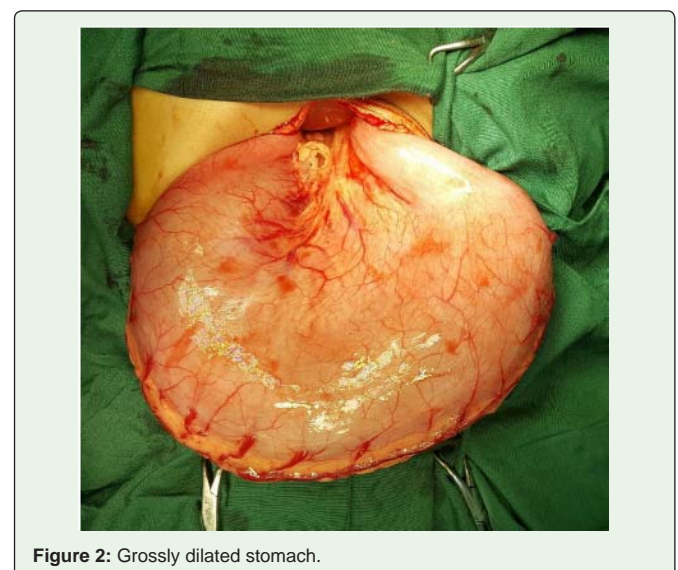


Figure 2: Grossly dilated stomach.

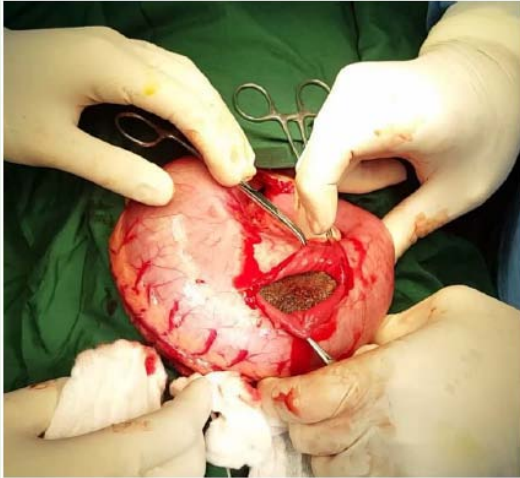


Figure 3: Anterior gastrotomy.

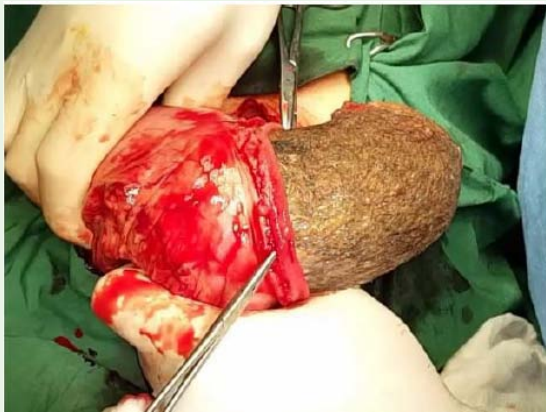

Figure 4: Delivery of trichobezoar through anterior gastrotomy.

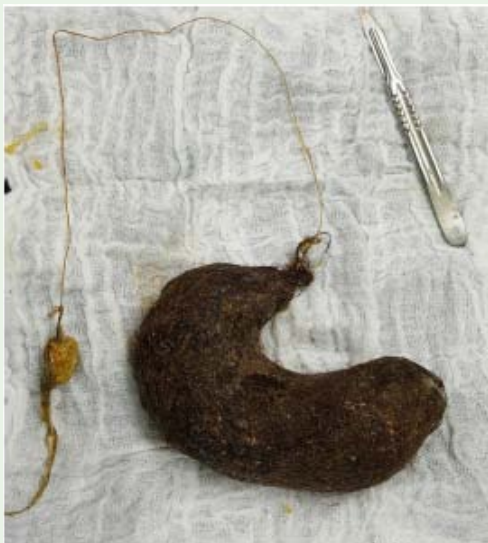

Figure 5: Completely extracted stomach-shaped trichobezoar with its tail extending to the small bowel.

The patient was transferred to the surgical ward. His postoperative recovery was good and uneventful; he was kept Nil Per Os (NPO) for five days, receiving intravenous fluid & electrolytes with broad-spectrum antibiotics. Oral feeds were started gradually in the fifth postoperative day. He was discharged home on seventh postoperative day. Psychiatric consultation was advised and child was followed up for a period of 1 year. No recurrence occurred.

Discussion

Trichobezoars constitute about 55% of all bezoars, 90% of cases occur in adolescent girls as mentioned in the classic review of literature [4,21] perhaps as a consequence of their long hair which makes it more prone to entanglement, entrapment in the gastric mucosal folds, become enmeshed and hence formation of trichobezoar casts [6]. However, it may occur in males as reported by Hirugade et al [22], which found that the reported patient ate the hair of his sisters. While the patient in this reported case was a boy with history of ingesting hair, carpet and clothing fibers from the ground. Rapunzel syndrome is a rare form of trichobezoar with only forty-one cases formally reported in the medical literature [11,23,24]. Various criteria have been used in its description in the literature; some defined it as a gastric trichobezoar with a tail extending up to the ileocaecal junction [11], some described it as a simple trichobezoar with a long tail, which may extend beyond pylorus up to the jejunum and some still define it as a bezoar of any size which can cause intestinal obstruction [14]. Here we reported a big mass of gastric trichobezoar with its long tail extended into the duodenum & small bowel and this is somewhat match with the aforementioned definitions.

In general, case reports of trichobezoars or Rapunzel syndrome in children are rare, and the Factors associated with trichophagia and trichobezoar formation in early childhood include child neglect, abuse, or bereavement [15,25], mental retardation, psychiatric conditions and underlying behavioral disorder leading to hair pulling (trichotillomania) and pica [14,11]. Our patient has no trichotillomania, but suffers from trichophagia. Some reports do suggest that delayed gastric emptying in postvagotomy patients may contribute to the formation of bezoars [26], but it has been suggested that impairment of the sieving and grinding mechanisms of the stomach, more than the emptying, is the factor contributing to the formation of bezoars [7].

The clinical Presentation of trichobezoar is usually late, due to the low index of suspicion by the clinician. It is reasonable to assume that the degree of shame or guilt was enough for the patient to denial history of trichotillomania or trichophagia and this is the case in our patient. trichobezoar has no pathognomonic symptoms or signs and the patient may remain asymptomatic for many years. The most common presenting complaints include bloating, nausea, early satiety, abdominal pain and weight loss [27,28]. The mass of large bezoars are often palpable, mobile and well defined in 90% of cases and it may be indentable (Lamerton's sign) [29]. It has been estimated that only 1% of patients with trichophagia develop a trichobezoar [30] Nevertheless, patchy alopecia with severe halitosis may provide clues on physical examination. Uncommonly, patients may vomit or pass fragments of hair with stools [31]. Trichobezoar may present as an emergency that surgeons should be prepared to deal with like perforation of either the stomach or the intestine. The blood supply to the gastric mucosa and part of the intestine may be reduced due to the presence of large eroding or obstructing mass

of bezoar, which may cause ulceration and subsequent perforation. Less commonly, patients may present with peritonitis, hematemesis and intussusception [24]. Other complications include obstructive jaundice, acute pancreatitis and gastric emphysema [32] and this later complication was noticed in our patient by abdominal CT scan.

The diagnosis of gastric trichobezoar can be confirmed by radiography or endoscopy. Plain abdominal films may reveal amorphous, granular or whirlpool-like configurations of solid and gaseous material within the stomach [33]. In some instances, the bezoar is so compact that a layer of air envelopes it, calcification is often observed with long-term accumulation. The ultrasonography has limited role in diagnosis because the high echogenicity of hair and the presence of multiple acoustic interfaces created by trapped air and food limit the ultrasonography of the trichobezoar [34-36], it shows a typical curvilinear trichobezoar with bright echogenic band. Here in this reported case, there was no conclusive finding on both plain abdominal film and ultrasound examination. The pathognomonic finding of the echogenic arc of air between the bezoar and the gastric wall on ultrasonography can be enhanced if fluid is administered concomitantly during the examination [36]. Upper gastrointestinal studies with use of contrast medium occasionally confirm the presence of a bezoar and may outline a concomitant gastric ulcer. Computed tomography vividly demonstrates trichobezoars as free-floating filling defects within the stomach, especially in the presence of orally administered contrast medium [37] as in this reported patient.

A definitive diagnosis of gastric bezoars can also be established by endoscopy. Furthermore, endoscopy of the duodenum is essential to rule out the possibility of extension of the tail of bezoars (Rapunzel syndrome) [38]. This subject has recently attracted attention about therapeutic options because of the argument about the application of minimally invasive techniques such as endoscopy and laparoscopy [39,40]. The proper therapy for any bezoar necessitates removal and prevention of recurrence. Small bezoars may be amenable to nasogastric lavage or suction, a clear liquid diet and the use of prokinetic agents. Bezoars may be fragmented mechanically or through the use of digestive enzymes but this is mainly for phytobezoar [40].

Endoscopic retrieval and fragmentation can be used for proximal bezoars whose size and density are not prohibitive; however, the procedure can be technically challenging, and fragments may migrate distally and cause small bowel obstruction [41]. Reports of successful endoscopic removal of trichobezoars are noteworthy rare, however; they are greatly outnumbered by case reports documenting unsuccessful trials of endoscopic removal in children with or without fragmentation [41-43]. Gorter et al in their literature review was able to identify 40 cases of endoscopic removal trials of gastric trichobezoar of which only two were successful (5%) [40]. However, in most case reports, fragmentation of trichobezoar mass was considered impossible because of its size, density and hardness, hence, endoscopy was not considered a viable therapeutic option. Moreover, as the removal of all fragments requires repeated introduction of the endoscope, several complications may ensue like pressure ulceration, esophagitis and even esophageal perforation [44]. Although endoscopy cannot be used for careful examination of the intestine for satellites, it may be proved extremely valuable as a diagnostic modality in patients whom the nature of the gastric mass is unclear.

Conclusion

Laparoscopy is considered inferior to laparotomy for the treatment of trichobezoar for many centers. Nirasawa et al [45] were the first to report on laparoscopic removal of a trichobezoar. Since then only six other reports of attempted laparoscopic removal were published [39,44,46]. Successful laparoscopic removal requires significantly longer operation time as compared to conventional laparotomy. Careful examination of the entire digestive system (stomach and intestine) is necessary in order to prevent secondary intestinal obstruction by satellites. The risk of spilling contaminated hair fragments out of bowel lumen into the peritoneal cavity makes the laparoscopic approach even less attractive.

Laparotomy is still considered the treatment of choice in many centers due to 100% success rate, relatively low complication rate, low complexity, and the ability to carefully check the entire gastrointestinal tract for satellites in a relatively short period of time [40]. Laparotomy is mandatory for bezoars that have complication of perforation, hemorrhage or are too large to be managed less invasively. Additionally in Rapunzel syndrome, we see no other valid option than conventional laparotomy. In our patient, abdominal Computed tomography demonstrates that the bezoar was calcified and of sufficient size that endoscopic fragmentation and retrieval was impossible. The standard approach is a gastrotomy and then gastric trichobezoars can be easily extracted with careful palpation of the duodenum and jejunum for hair balls that may have broken off from the primary mass as was the case in this patient! The prevalence of a concurrent intestinal bezoar with gastric bezoar discovered at laparotomy is 20% [47]. At laparotomy, often the bezoar along with its tail can be retrieved through single gastrotomy, but at some occasions, multiple enterotomies are required to avoid the risk of gut perforation because the long trichobezoars are usually adherent with the gut wall and difficult to be removed through single enterotomy [48]. In this case report, the long bezoar was removed easily via the single gastrotomy without complications. Novel therapies include extracorporeal shock wave lithotripsy and Nd:YAG laser, a new mini-explosive technique through an endoscope has claimed 100% success in China [49,50]. Specialized bezotomes and bezotriptors (medical devices that pulverize bezoars either mechanically or with acoustic waves) have been used to fragment large and solid trichobezoars [14].

After removal of trichobezoar, the prognosis is good if psychiatric therapy to control pica and habitual trichophagia is successful. Recurrence of trichobezoar is expected if the underlying emotional stress factor is not resolved [48].

References

1. Williams RS. The fascinating history of bezoars. *Med J Aust.* 1986; 145: 613-614.
2. Shorter E. *A historical dictionary of psychiatry.* Oxford University Press: New York. 2005.
3. Sehgal VN, Srivastava G. Trichotillomania ± trichobezoar: revisited. *Eur Acad Dermatol Venereol.* 2006; 20: 911-915.
4. DeBakey M, Ochsner W. Bezoars and concretions: A comprehensive review of the literature with an analysis of 303 collected cases and a presentation of 8 additional cases. *Surgery.* 1939; 5: 132-160.
5. Bouwer C, Stein DJ. Trichobezoars in trichotillomania: Case report and literature overview. *Psychosom Med.* 1998; 60: 658-660.

6. Frey AS, McKee M, King RA, Martin A. Hair apparent: Rapunzel syndrome. *Am J Psychiatry*. 2005; 162: 242-248.
7. Coulter R, Antony MT, Bhuta P, Memon MA. Large gastric trichobezoar in a normal healthy woman: Case report and review of pertinent literature. *Southern Med J*. 2005; 98: 1042-1044.
8. Salaam K, Carr J, Grewal H, Sholevar E, Baron D. Untreated trichotillomania and trichophagia: Surgical emergency in a teenage girl. *Psychosomatics*. 2005; 46: 362-366.
9. Katharine E, Marsha K. Gastrointestinal bezoars: history and current treatment paradigms. *J Gastroenterol Hepatol*. 2012; 8: 776-778.
10. Sah DE, Koo J, Price VH. Trichotillomania. *Dermatol Ther*. 2008; 21: 13-21.
11. Naik S, Gupta V, Rangole A, Chaudhary AK, Jain P, Sharma AK. Rapunzel syndrome reviewed and redefined. *Dig Surg*. 2007; 24:157-161.
12. Vaughan ED, Sawyers JL, Scott HW. The Rapunzel syndrome. An unusual complication of intestinal bezoar. *Surgery*. 1968; 63: 339-343.
13. Curioso Vilchez WH, Rivera Vega J, Curioso Abriojo WI: Rapunzel syndrome: case report and literature review. *Rev Gastroenterol Peru*. 2002; 22: 168-172.
14. Gonuguntla V, Joshi DD. Rapunzel syndrome: a comprehensive review of an unusual case of trichobezoar. *Clinical medicine and research*. 2009; 7: 99-102.
15. Ventura DE, Herbella FAM, Schettini ST, Delmonte C. Rapunzel syndrome with a fatal outcome in a neglected child. *J Pediatr Surg*. 2005; 40:1665-1667.
16. Mehta MH, Patel RV. Intussusception and intestinal perforations caused by multiple trichobezoars. *J Pediatr Surg*. 1992; 27:1234-1235.
17. Schreiber H, Filston HC. Obstructive jaundice due to gastric trichobezoar. *J Pediatr Surg*. 1976; 11:103-104.
18. Hossenbocus A, Colin-Jones DG. Trichobezoar, gastric polyposis, protein losing enteropathy and steatorrhea. *Gut*. 1973; 14: 130-132.
19. Shawis RN, Doig CM. Gastric trichobezoar with transient pancreatitis. *Arch Dis Child*. 1984; 59: 994-995.
20. Carr JR, Sholevar EH, Baron DA. Trichotillomania and trichobezoar: A clinical practice insight with report of illustrative case. *J Am Osteopath Assoc*. 2006; 106: 647-652.
21. Sood AK, Bahl L, Kaushal BK. Childhood Trichobezoar. *Indian Journal of Paediatrics*. 2000; 67: 390-391.
22. Hirugade ST, Talpallikar MC, Deshpande AV, Gavali JS, Borwankar SS. Rapunzel syndrome with a long tail. *Indian J Pediatr Surg*. 2001; 68: 895-896.
23. Kohler JE, Millie M, Neuger E. Trichobezoar causing pancreatitis: first reported case of Rapunzel syndrome in a boy in North America. *J Pediatr Surg*. 2012; 47: e17-e19.
24. Anantha RV, Chadi SA, Merritt N. Trichobezoar causing intussusception: Youngest case of Rapunzel syndrome in a boy in North America. *J Ped Surg Case Reports*. 2013; 1: e11-e13.
25. Armstrong JH, Holtzmuller KC, Barcia PJ. Gastric trichobezoar as a manifestation of child abuse. *Curr Surg*. 2001; 58: 202-204.
26. Brady PG. Gastric phytobezoars consequent to delayed gastric emptying. *Gastrointest Endosc*. 1978; 24: 159-161.
27. Rutkoski JD, Gittes GK. Bezoar-related stercoral perforation in an 11-year old child: Has anyone seen my other sock? *Journal of Pediatric Surgery Case Reports*. 2015; 3: 219-222.
28. Sinha AK, Vaghela MM, Kumar B, Kumar P. Pediatric gastric trichobezoars with acute life threatening and undifferentiated elective bipolar clinical presentations. *Journal of Pediatric Surgery Case Reports*. 2017; 16: 5-7.
29. Lamerton AJ. Trichobezoar: Two Case Reports- A New Physical Sign. *American Journal of Gastroenterology*. 1984; 79: 354-356.
30. Irving PM, Kadiramanathan SS, Priston AV, Blanshard C. Education and imaging. *Gastrointestinal: Rapunzel syndrome*. *J Gastroenterol Hepatol*. 2007; 22: 2361.
31. Sharma V. Gastrointestinal Bezoars. *Journal of the Indian Medical Association*. 1991; 89: 338-339.
32. Klipfel AA, Kessler E, Schein M. Rapunzel syndrome causing gastric emphysema and small bowel obstruction. *Surgery*. 2003; 133: 120-121.
33. Wadlington WB, Rose M, Holcomb OW Jr. Complications of trichobezoars: a 30-year experience. *South Med J*. 1992; 85: 1020-1022.
34. Hoovera K, Piotrowski J, Pierreb K, Katzc A, Goldsteinb AM. Simultaneous gastric and small intestinal trichobezoars: A hairy problem. *J Pediatric Surg*. 2006; 41:1495-1497.
35. Roche C, Guye E, Coinde E, Galambrun C, Glastre C, Halabi M, et al. Trichobézoard: À propos de 5 observations. *Arch Pédiatr*. 2005; 12: 1608-1612.
36. Newman B, Girdany BR. Gastric trichobezoars-sonographic and computed tomographic appearance. *Pediatr Radiol*. 1990; 20: 526-527.
37. Billaud Y, Pilleul F, Valette PJ. Mechanical small bowel obstruction due to bezoars: Correlation between CT and surgical findings. *J Radiol*. 2002; 83: 641-646.
38. Shadwan A, Mohammad A. Small bowel obstruction due to trichobezoar: Role of upper endoscopy in diagnosis. *Gastrointest Endoscop*. 2000; 52: 784-786.
39. Palanivelu C, Rangarajan M, Senthikumar R, Madankumar MV. Trichobezoars in the stomach and ileum and their laparoscopy- assisted removal: a bizarre case. *Singapore Med J*. 2007; 48: 37-39.
40. Gorter RR, Kneepkens CM, Mattens EC, Aronson DC, Heij HA. Management of trichobezoar: case report and literature review. *Pediatric surgery int*. 2010; 26: 457-463.
41. Alsafwah S, Alzein M. Small bowel obstruction due to trichobezoar: role of upper endoscopy in diagnosis. *Gastrointest Endosc*. 2000; 52: 784-786.
42. Wang YG, Seitz U, Li ZL, Soehendra N, Qiao XA. Endoscopic management of huge bezoars. *Endoscopy*. 1998; 30: 371-374.
43. Van Gossum A, Delhay M, Cremer M. Failure of non-surgical procedures to treat gastric trichobezoar. *Endoscopy*. 1989; 21:113.
44. Kanetaka K, Azuma T, Ito S, Matsuo S, Yamaguchi S, Shirono K et al. Two-channel method for retrieval of gastric trichobezoar: report of a case. *J Pediatr Surg*. 2003; 38: 1-2.
45. Nirasawa Y, Mori T, Ito Y, Tanak H, Seki N, Atomi Y. Laparoscopic removal of a large gastric trichobezoar. *J Pediatr Surg*. 1998; 33: 663-665.
46. Meyer-Rochow GY, Grunewald B. Laparoscopic removal of a gastric trichobezoar in a pregnant woman. *Surg Laparosc Endosc Percutan Tech*. 2007; 17: 129-132.
47. Phillips MR, Zaheer S, Drugas GT. Gastric trichobezoar: case report and literature review. In *Mayo Clinic Proceedings*. 1998; 73: 653-656.
48. Memon SA, Mandhan P, Qureshi JN, Shairani AJ. Recurrent Rapunzel syndrome-a case report. *Medical Science Monitor*. 2003; 9: CS92-94.
49. Huang YC, Liu QS, Guo ZH. The use of laser ignited mini-explosive technique in treating 100 cases of gastric bezoars. *Zhonghua Nei Ke Za Zhi*. 1994; 33: 172-174.
50. Benes J, Chmel J, Jodl J, Stuka C, Nevorál J. Treatment of a gastric bezoar by extracorporeal shock wave lithotripsy. *Endosc*. 1991; 23: 346-348.