

Flexible Way to Encircle the Inferior
Vena Cava in Minimally-Invasive
SurgeryJuan-Miguel Gil-Jaurena^{1,2}, Pita Ana^{1,2} and De la Torre Manuel³¹Department of Pediatric Cardiac Surgery, Gregorio Marañón Hospital, Madrid, Spain²Instituto de Investigación Sanitaria Gregorio Marañón, Madrid, Spain³Department of Pediatric Surgery, Hospital Gregorio Marañón Madrid, Spain

Article Information

Received date: May 11, 2018

Accepted date: May 16, 2018

Published date: May 18, 2018

*Corresponding author

Juan-Miguel Gil-Jaurena, Department of Pediatric Cardiac Surgery, Gregorio Marañón Hospital, Madrid, Spain,
Tel: +00 34 91 529 0267;
Email: giljaurena@gmail.com

Distributed under Creative Commons
CC-BY 4.0

Abstract

A new and simple trick to encircle the Inferior Vena Cava (IVC) in minimally invasive cardiac surgery is depicted. With the aid of a shafted, flexible-tip dissector, the IVC is surrounded with a tape for its exclusion in a gentle movement.

Minimally invasive cardiac surgery has reached its adulthood [1-4]. Many groups report their outstanding results and pave the way with tips and pitfalls for the sake of anyone's learning curve [5]. Our own group has been performing minimally invasive congenital cardiac surgery for more than fifteen years [6], incorporating new approaches and addressing new cardiac conditions as experience and technology evolves. Surgical closure of an ostium secundum atrial septal defect, not amenable to percutaneous management, is presented to illustrate a new trick. A three year-old and 17 Kg. female was scheduled for an axillary approach to have her cardiac defect addressed. The inferior vena cavae, quite distant from the tiny incision, proved somehow difficult to be encircled. A flexible-tip dissector enabled us to pass the tape around the vena cave and eventually secure it (video clip). The procedure was straightforward thereafter, with an uneventful recovery before discharge on 5th postoperative day.

Several tools, either borrowed from other surgical disciplines (soft tissue retractor, shafted instruments) or specifically designed for cardiac surgery (trans-thoracic and flexible aortic clamps) have been added step by step to deal with hurdles in the way. One of the latest issues to be addressed is how to encircle the Inferior Vena Cava (IVC) from a distant and narrow approach. Regular dissectors are cumbersome to drive because little room is left to rock them through a tiny entrance. Deployment of bulldogs (with a shafted forceps) is an alternative when peripheral cannulation is employed.

Looking for a long, bendable-tip instrument (Figure 1) we bump into SILSTM Dissect (Covidien, 555 Long Wharf Drive, New Haven, CT, USA). It is commonly used in single incision laparoscopic surgery (SILS) by our colleagues in Pediatric Surgery, and proved useful to tackle our purpose. Once on by-pass and with an empty decompressed heart, blunt dissection between the IVC and right inferior pulmonary vein is carried out. Having developed the oblique sinus, the instrument, with a folded tape grabbed in its tip (Figure 2A), is slipped under the IVC. Then, after reaching 90 degrees deflection, the folded tape on the tip appears above the IVC pointing towards the operator (Figure 2B). Finally, the tape is grasped with shafted forceps and the flexible dissector is released.

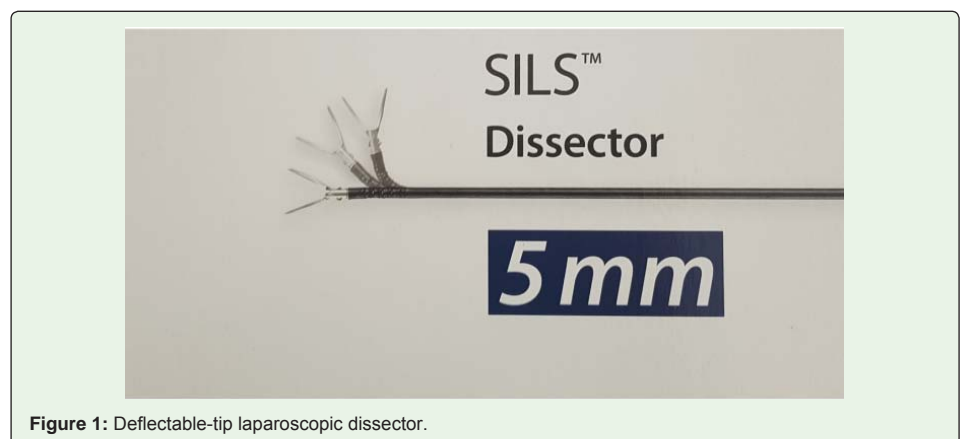

Figure 1: Deflectable-tip laparoscopic dissector.

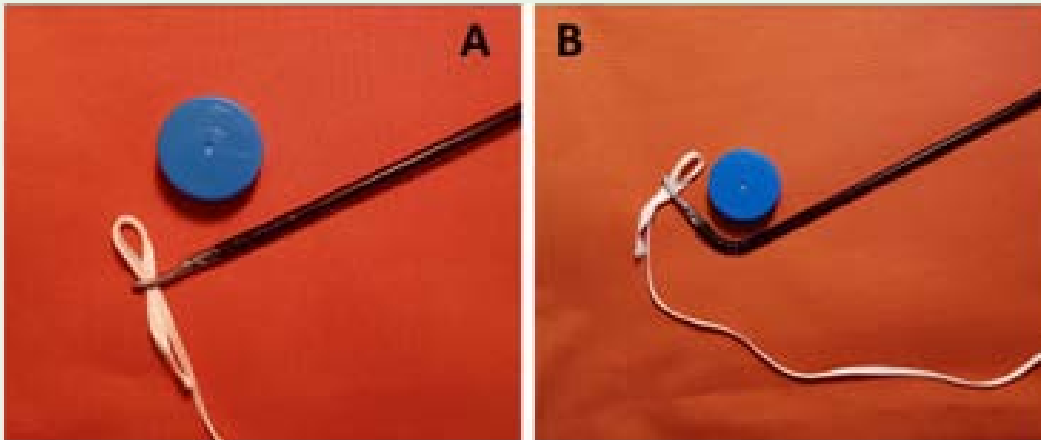
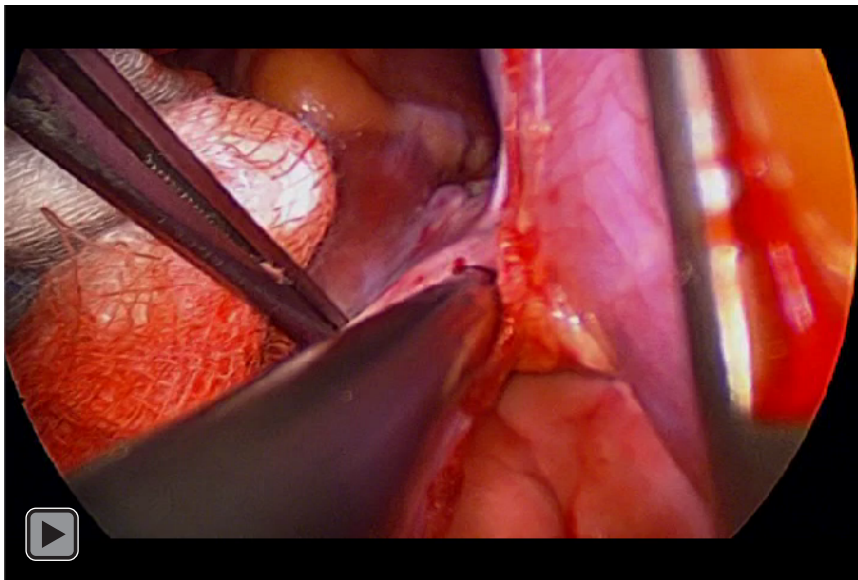


Figure 2A: Dissector slipped under the inferior vena cava (blue circle), grasping a folded tape.
2B: Bended dissector, providing a stiff and “C-like” shape device to be grabbed.



Video 1: Bendable dissector under inferior vena cavae.

The authors find this easy maneuver particularly appealing for video-assisted mini-thoracotomy approaches (3-4 cm incision) and axillary entrance through the third intercostal space in small children (5-6 cm incision) which is our usual approach for sinus venosus atrial septal defect with partial anomalous pulmonary venous drainage in the superior vena cava. In both cases, the IVC is somehow distant from the tiny surgical incision. Grasping the tape in a folded way provides it with a stiffer and “C-like” shape after deflection, making it easier to be caught by the surgeon.

Conclusion

Transition to minimally invasive surgery deserves commitment and confidence towards proficiency. Commitment to keep the same or even better results than standard approaches [7]. Confidence that

any “unsurmountable” hurdle can be overcome [8] with bold tricks and new tools; sometimes, found next door.

Video clip

Bendable dissector under inferior vena cavae.

References

1. Mohr FW, Falk V, Diegeler A, Walther T, van Son JA, Autschbach R. Minimally invasive port-access mitral valve surgery. *J Thorac Cardiovasc Surg.* 1998; 115: 567-574.
2. Casselman FP, Van Slycke S, Dom H, Lambrechts DL, Vermeulen Y, Vanermen H. Endoscopic mitral valve repair: feasible, reproducible, and durable. *J Thorac Cardiovasc Surg.* 2003; 125: 273-282.

3. Modi P, Hassan A, Chitwood WR Jr. Minimally invasive mitral valve surgery: a systematic review and meta-analysis. *Eur J Cardiothorac Surg.* 2008; 34: 943-952.
4. Argenziano M, Oz MC, Kohmoto T, Morgan J, Dimitui J, Mongero L, et al. Totally endoscopic atrial septal defect repair with robotic assistance. *Circulation.* 2003; 108(Suppl 1): II191-94.
5. Bonaros N, Schachner T, Oehlinger A, Ruetzler E, Kolbitsch C, Dichtl W, et al. Robotically assisted totally endoscopic atrial septal defect repair: insights from operative times, learning curves, and clinical outcome. *Ann Thorac Surg.* 2006; 82: 687-693.
6. Gil-Jaurena JM, González-López MT, Pérez-Caballero R, Pita A, Castillo R, Miró L. Fifteen years of minimally invasive pediatric cardiac surgery; development and trends. *An Pediatr.* 2016; 84: 304-310.
7. Chu MW, Losenno KL, Fox SA, Adams C, Al-Habib H, Guo R, et al. Clinical outcomes of minimally invasive endoscopic and conventional sternotomy approaches for atrial septal defect repair. *Can J Surg.* 2014; 57: E75-81.
8. Gil-Jaurena JM, Pérez-Caballero R, Pita-Fernández A, González-López MT, Sánchez J, De Agustín JC. How to set-up a program of minimally invasive surgery for congenital heart defects. *Transl Pediatr.* 2016; 5: 125-133.