

## Pediatric lumbar disk herniation

Siriwardena KMDL\*

Sichuan University, West China School of medicine, China

## Article Information

Received date: Oct 08, 2018

Accepted date: Oct 12, 2018

Published date: Oct 16, 2018

## \*Corresponding author

Siriwardena KMDL, Sichuan University,  
West China School of medicine, China,  
Email: 1955063332@qq.com

Distributed under Creative Commons  
CC-BY 4.0

**Keywords** Adolescent; Children;  
Pediatric; Lumbar disc herniation;  
Lumbar vertebrae; Low back pain;  
Lumbar disc disease

**Abbreviations** LDH: Lumbar Disc  
Herniation; PLDH: Pediatric Lumbar  
Disk Herniation; ROM: Range of  
Motion; NSAIDs: Nonsteroidal Anti-  
Inflammatory Drugs; SLR: Straight Leg  
Raising Test; PELD: Percutaneous  
Endoscopic Lumbar Discectomy; PEID:  
Percutaneous Endoscopic Interlaminar  
Discectomy; PETD: Percutaneous  
Endoscopic Transforaminal  
Discectomy; MD: Microdiscectomy;  
OLD: Open Lumbar Discectomy; MED:  
Microendoscopic Discectomy

## Abstract

Lumbar Disk Herniation (LDH) is one of the most common disorders among adults with degenerated lumbar intervertebral discs [1]. However, its occurrence in childhood and adolescence is less frequent mostly because children and adolescents tend to have a healthier lumbar spine as compared with adults [2]. The main factors associated with LDH in children are trauma with subsequent axial load or a sport-related injury in some findings [2-4]. According to previous publications, pediatric patients constituted 0.5% to 6.8% of all patients hospitalized for LDH [1]. Hence the structural malformations in the lumbar spine could predispose intervertebral disks to early degeneration; it is usually recommended to be fused surgically [2,4].

The aim of the present review is to provide the latest clinical information and findings of pediatric LDH. Since the disease is rare among pediatric population this article would be helpful to overcome the typical delay in diagnosis compared with the adult LDH.

## Introduction

Lumbar disc herniation is a relatively rare disorder in pediatric population compared with adults, with approximately 5% of lumbar disc disease occurring in patients younger than 18 years of age [3]. Cervical and thoracic disk herniation cases are quite rare and generally there is no specific literature found on that issue in children and adolescents. So the present study is mainly focused on lumbar disc herniation.

Unlike adults, where chronic degenerative changes are main cause, the main factors associated with LDH in children are trauma with subsequent axial load or a sport-related injury is significant [1,2,4]. Patients with lumbar disc disease often suffer from new onset low back pain and lower extremity radiculopathy. Furthermore majority of patients may only have radicular symptoms [5]. However the issues unique to pediatric LDH can lead to relative delay in establishing the diagnosis and inappropriate courses of treatment that might not be effective in pediatric population. Awareness of LDH helps us exact a relevant medical history, perform a directed physical examination and order appropriate imaging studies [3]. This will aid in initiating early intervention, be it conservative or operative for achieving a favorable outcome.

The purpose of this article is to review the fundamentals of pediatric lumbar disc herniation by emphasizing etiology, pathogenesis, radiological features and treatment strategies. Since the LDH in pediatric population is dissimilar from that in adults, this review will help to differentiate an initial diagnosis for the patients.

## Clinical Epidemiology

Accurate occurrence of LDH in pediatrics is usually supposed to be inferior to that in adults. Relevant studies have shown that children represent only 0.5% to 6.8% of all patients hospitalized for LDH [1]. Generally lumbar disc herniation occurs rarely during the first decade of life. However the literature shows most children with the matters related to LDH haven't been examined until the age of 15 years, whereas this number augmented to the range of 0.1%-0.2% while the subjects were 20 years old [6].

There is no evident of gender prominence of disk herniation in pediatric population. Some studies have shown a female predominance, although some other series have found a slight male prominence [3].

## Etiology

The possible causes of pediatric LDH have recognized in numerous aspects. Trauma especially from sport injuries measured as 30%-60% of children and adolescents with symptomatic LDH which can be identified by a previous history of trauma prior to the beginning of the pain. Furthermore, decreased range of motion (ROM), poor conditioning, excessive or repetitive axial loading and improper technique are highly related to this condition [2,5]. In addition, heavy lifting and athletic activities that result in falls are also associated with increased risk of disk herniation. Moreover, engaging in new training proposes that instead of being a main determining factor, trauma is expected to be a provocative occasion in the exacerbation of the prevailing lesions of

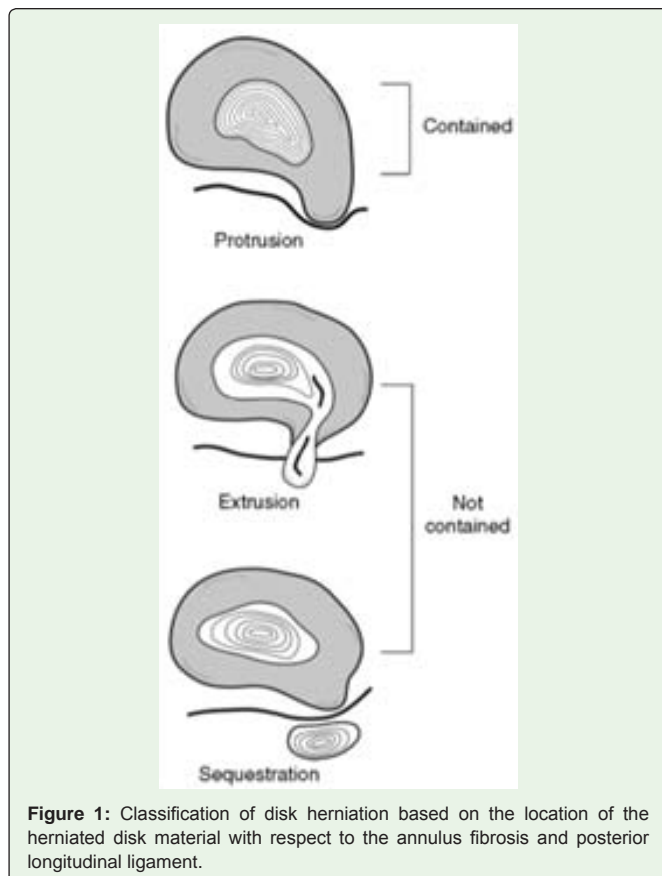
the discs. Additionally genetic factors are documented as a common source of pediatric LDH. Studies have shown that between 13 and 57% of adolescents with LDH has a first-degree relative with the same disorder [1,2].

Other vertebral abnormalities related to LDH has been recognizes as scoliosis and transitional vertebra, even though their further studies haven't been measured yet. Furthermore, there are findings about a few trainings representative of the connotation of epiphyseal ring division with LDH of pediatric population which coincidentally rate up to 40 % [2].

This association can be defined by the presence of weak connective tissue with a predisposition to developing degenerative changes in the spine and disk herniation at a younger age compared with the overall population.

### Pathophysiology

Disk herniation is occurred by injury to the annulus fibrosis that allows nuclear material to escape. Herniation generally occurs during motions that cause increased intradiscal pressure, such as lumbar flexion, axial compression and rotational movements. The outer one third of the annulus is innervated; hence the pain occurs initially. Lately it may progress to radicular symptoms as nuclear material exit and cause irritation of the surrounding nerve root. The segmental distribution of disk herniation is similar in children to that seen in adults. The L4-L5 and L5-S1 levels describe over 50% of all disc herniations [3].



**Figure 1:** Classification of disk herniation based on the location of the herniated disk material with respect to the annulus fibrosis and posterior longitudinal ligament.

Compared with adults, pathological studies of herniated disks in children show more elastic consistency with high water content [3]. This leads to the less responsiveness to conservative treatment and require operative intervention. Studies have shown that underlying abnormalities can be also associated with lumbar disk herniation including occult spina bifida, extra lumbar vertebra, sacralization of the fifth lumbar vertebra, spinal and lateral recess stenosis and spondylolisthesis.

Generally herniations can be classified into three categories: protrusion, extrusion, and sequestration (Figure 1) [5]. Protrusion is a circumferential symmetric bulging of the disk over the vertebral borders. Disk extrusion is a prolonging of the disk beyond the vertebral border and through some layers of the annulus and the extruded material and the disk of origin has in-between connection. However in sequestration, the disk of origin has no connection with the herniated disk. Hence the disk material passes through the annulus and posterior longitudinal ligament in sequestration and extursions, can be classified as noncontained disk herniations.

Classification of disk herniation based on the location of the herniated disk material with respect to the annulus fibrosis and posterior longitudinal ligament.

LDH can also be classifies as central and paracentral by location [5]. These types typically compress the traversing nerve root, since far lateral and extraforaminal disk herniations typically compress the exiting never root. Majority of disk herniations are contained and paracentral. These specific pathological findings cause the difference of initial treatment strategies from adult LDH patients.

### Diagnosis

#### Clinical history

Typically pediatric patients who have symptomatic lumbar disk herniation present with a new-onset of low back pain and radiculopathy of lower extremities. Symptomatic disk herniation is mostly reported after trauma or sports related injury in 30%-60% of pediatric LDH population where the symptoms appear within a few hours of the injury. Many pediatric patients may only present low back pain, since neurological symptoms such as numbness and weakness are relatively rare in this group of patients [2].

However due to the less specific description about the pain than do adults and overall low incidence of the disease in children, it leads significantly longer mean of duration for correct diagnosis (10 months) as compared with adult patients( 4.7 months) [3].

Therefore a thorough clinical history should be obtained to determine the onset of pain, the provoking activity and the amount of training involved. The location, severity, and radiation of the pain should be specifically noted. Pain exacerbating on flexion or valsalva maneuvers may suggest intervertebral disk involvement. Pain getting worse during extension suggests involvement of posterior elements such as facet injury and spondylolysis [3].

Changes in neurological symptoms such as bowel and bladder dysfunction should be noted whereas it is important to rule out cauda equine syndrome. Response to medications such as Nonsteroidal Anti-Inflammatory Drugs [NSAIDs] should be elicited, as well as prior back pain and underlying medical conditions.

**Physical examination**

Firstly the clinicians should examine the postural abnormalities, compensatory positioning and gait abnormalities. A complete spine inspection is necessary for the inspection of areas of tenderness, palpable masses, edema and malalignment.

ROM of flexion, extension, lateral bending, and rotation should be assessed. Patients with disk herniation commonly experience global loss in ROM, and they are often acutely stiff. The knees must be fully extended during flexion and extension and the pelvis must be stable during ROM activities. In LDH, typically the pain exacerbate on flexion [5].

Furthermore sensory assessment using pinprick, light touch and proprioceptive sense is essential. Manual motor testing and deep tendon reflexes should be conducted as well. Assessment of the popliteal angle can help quantify excessive hamstring tightness and an angle >45° is common in patients with severe back pain [5].

A Straight Leg Raise (SLR) test is the most common tension sign used to diagnose LDH [3]. Approximately 90% of patients with LDH have a positive SLR test which explains that children and adolescents are tend to have a greater nerve root tension than adults. Moreover one third have a positive crosses SLR test.

Findings show that approximately 90% of symptomatic disk herniation occurs at vertebral levels L4-L5 and L5-S1. L5 nerve root is commonly affected by herniation at L4-L5 levels. Therefore weakness of the extensor hallucis longus muscle may be seen with L5 nerve root compression. There is no deep tendon reflex associated with the L5 nerve root, but sensory abnormalities may be seen in the dorsum of the foot [5,7,8].

Disk herniation at the vertebral level of L5-S1 generally affect S1 nerve root and may lead to weakness of ankle plantar flexion and eversion. The Achilles tendon reflex should be tested to examine the function of S1 nerve root. Sensory testing should be conducted at the lateral foot and the lateral lower leg.

The following table (Table 1) shows the details of the vertebral levels involved in disk herniation of the pediatric population [4].

**Radiological examinations**

The first type of imaging obtained in adolescents with suspected spinal pathology is plain radiographs. Radiographs are abnormal in 50%-70% of children with LDH. The AP view is used to evaluate scoliosis and congenital anomalies such as transitional vertebrae and lateral view is useful in identifying of spondylolisthesis, disk height abnormalities, and the presence of vertebral fractures or defects of the pars interarticularis [5]. Segmental instabilities are evaluated by flexion and extension radiographies. However radiographic information is inadequate for visualizing disk herniations.

MRI is the standard imaging technique for LDH except when acute spine fractures are suspected. It has an excellent resolution of the disks, neural elements and soft tissues. MRI is also helpful in identifying syringomyelia, spinal tumors, and other soft tissue abnormalities of the spine [7].

However, if MRI is contraindicated the conventional or CT myelography can usually be performed in the following population.

The contrast medium illustrates the neural elements and compressive material. Even though CT myelography provides excellent bony detail and highlights neural compression, it is not useful in characterizing nonosseous structures such as intervertebral disks and tumors [3,5].

CT remains quite important in diagnosing or excluding an apophyseal and pars defect because of its ability to delineate bone. This should be considered preoperatively, particularly for large disk herniations.

**Differential Diagnosis**

Diagnoses in differential include facet injury, slipped epiphysis, spondylolysis and spondylolisthesis. Other infrequent conditions can comprise schmorl’s nodes, lumbar scheuermann disease, and apophyseal injuries of the posterior end plate. Moreover, conversion disorder, piriformis syndrome, secondary gain, spinal tumor, infection and malingering are extremely rare in pediatric patients [1,3,5].

**Management**

**Conservative treatment**

Conservative treatment is generally recommended as the first-line treatment for LDH in pediatric population without neurological deficits. It consists of bed rest, medication, physical therapy and limitation of physical activity. Medication including NSAIDs, muscle relaxants, and oral corticosteroids are helpful in pain management. Physical therapy is initiated with emphasis on aerobic exercise, peripelvic flexibility, core stabilization, and conditioning specific to activities or sports. Activities such as prolonged sitting, jumping, spine hyperflexion or extension, and straining are avoided since they increase intradiscal pressure and may aggravate symptoms [2-6].

There are also limited reports on the use of epidural steroid injections as a part of conservative treatments for pediatric. Some literature indicates that the epidural steroid injection treatment produced symptomatic relief; thereby allow patients the time to respond to nonsurgical treatment [2-6].

Compared outcome of conservative treatment with surgical treatment has found that surgical treatment lead to a significant better outcome than conservative treatment. It has been widely agreed by most studies that conservative treatment is not as effective for pediatric LDH as that is for adults.

There are several explanations for unsatisfied results of conservative treatment: [9] the herniated nucleus pulposus of

**Table 1:** The following table shows the details of the vertebral levels involved in disk herniation of the pediatric population [12].

Level of disc	Percentage of patients [%]
L4-5	52%
L5-S1	16%
L3-4	16%
L2-3	4%
L4-5,L5-S1	8%
L3-4,L4-5	4%

(L-Lumbar vertebra, S-sacral vertebra)

children is less degenerated, more hydrated, soft and viscous; it does not dry up and reabsorb like a degenerated adult disc [10]. Pediatric LDH is usually associated with trauma where annulus fibrosis could be severely ruptured [11]. The epiphyseal cartilage of the vertebral body in children and adolescents is not fully fused; therefore severe trauma could rupture the epiphyseal ring forming a large impulsive mass along with the herniated disc [1]. Children and adolescents are active and complying strict bed resting is relatively difficult [2].

### Intradiscal therapy

According to the studies, chemonucleolysis was the only form of intradiscal therapy reported being used on children and adolescents [2-6]. Chemonucleolysis is a procedure in which chymopapain is injected into vertebral disk space. Indications for chemonucleolysis as following: [9] patients with leg pain more severe than back pain [10] severely limited straight-leg raising test [11] soft disc herniation confirmed by CT.

Compared with surgery, chemonucleolysis is advantageous in that it is associated with less trauma and post-operative adhesion, shorter hospital stay, earlier remobilization and lower cost. Disadvantages are the limited capacity of nuclear removal and uncertain nerve root decompression; therefore it is not suitable for severely extruded discs.

Increased back pain is the most common symptom after injection, but it can be controlled with medication. Leakage of contrast medium during injection tends to have no effect on clinical outcome. However currently, chymopapain is not recommended in the treatment of pediatric population with LDH.

### Surgical treatments

Surgical management of lumbar disk herniation interferes in patients who have failed nonsurgical therapy and in patients with progressive neurologic deficit or debilitating pain [2-6].

Indications generally agree in the literature include:

1. Severe pain intractable to 4-6 weeks of conservative treatment.
2. Incapacitating pain affecting one's daily activities
3. Cauda equina syndrome
4. Advanced neurological deficits
5. Correlating spinal deformities

Modalities of surgical treatment for pediatric lumbar disk herniation consist of percutaneous endoscopic lumbar discectomy (PELD also known as microendoscopic discectomy) and open discectomy including microsurgical discectomy or Microdiscectomy (MD), discectomy with laminotomy or laminectomy and spinal fusion.

### Open Discectomy

Discectomy remains the commonly used surgical procedure for LDH in children and adolescents. Generally posterior discectomy with partial laminotomy is required for posterolateral disc herniation, although semilaminotomy or laminectomy is indicated in cases of central disc herniation [2-6].

There were also reports on use of extraperitoneal anterolateral discectomy on centrally protruded disc successfully. Recent studies show that MD has also been used for the treatment of pediatric LDH and associated with good outcome.

Compared with PELD, discectomy is associated with more sufficient decompression. Nevertheless, extensive dissection of soft tissues can result in post-operative back pain. Excessive root manipulation during discectomy is more likely to cause nerve damage since pediatric patients have a greater nerve root tension than adults.

### Percutaneous Endoscopic Lumbar Discectomy (PELD)

Percutaneous Endoscopic Lumbar Discectomy (PELD), which is a minimally invasive alternative to the open procedure consist of two major techniques. They are named according to the difference in approach. The first procedure is Percutaneous Endoscopic Transforaminal Discectomy (PETD), in which the instruments are inserted and the herniated discs are removed posterolaterally via the intervertebral foramen. The other technique is Percutaneous Endoscopic Interlaminar Discectomy (PEID, in which the instruments are inserted in a posterior approach, through the interlaminar window to the herniated discs. Under direct visualization, the herniated discs can be removed [2-6].

The recommended indications of PELD for pediatric LDH are as follows: [9] Failure of 6 weeks of conservative treatment [10] A comparatively intact disc [11-38] Subligamentously protruded or extruded disc.

When comparing PETD with PEID, PEID shows its unique advantages. Without the limitation of bony foramen and blockage of pelvis, the PEID procedure can result in better mobility. Especially when there are sequestered or dislocated fragments that need to be removed, PEID is the classic and most familiar approach for spinal surgeons [8].

Compared with the open discectomy, PEID has the advantage of minimal traumatization to the normal spinal structures such as ligament flavum, muscle, lamina, and facet joint. It could avoid the resection of these stability preserving structures, which could minimize iatrogenic instability. Minimizing trauma to paraspinal structures such as the ligament flavum also means less epidural scar tissue formation.

Recent studies have also shown PEID to be safe and effective in managing pediatric LDH. With regard to intraoperative blood loss, hospital stay and postoperative complications, patients under PEID show better outcome than those underwent conventional Open Laminectomy and Discectomy (OLD) or Microendoscopic Discectomy (MED), with the same effect of recurrence and pain relief [2,7,8].

Moreover in previous studies reveal that although the Pediatric Lumbar Disk Herniation (PLDH) patients who underwent open discectomy with good short-term outcome, 20-30 % of patients need additional surgery later in their life. So the minimally invasive nature of PEID is expected to be especially beneficial for pediatric LDH population. However, requires a correct selection of patients and the surgeon being able to master the surgical procedure for best long term outcomes of the surgery.



**Table 2:** The following table compares the surgical results regarding different operation methods used in China.

Variables	MED	PELD	OLD
No. of patients (%)	80	25	16
Operating time (min)	82.6±40.2	92.4±34.6	80.9±31.4
Intraoperative bleeding (ml)	50.8±44.3	14.9±12.6	113.1±87.4
Postoperative drainage (ml)	0	0	45.8±24.8
Hospitalization in ICU (d)	0	0	1.4±0.6
Postoperative hospital stay (d)	7.3±2.9	4.4±2.6	10.6±4.2
Total hospital stay (d)	11.2±5.9	7.8±3.2	16.9±9.8
Hospitalization cost (x103 CNY)	11.9±3.9	10.2±2.8	11.7±3.8
No. of operative complications (%)	3 (3.8%)	1 (4.0%)	1 (6.3%)

(MED: Micoendoscopic discectomy, PELD: Percutaneous endoscopic lumbar discectomy, OLD-Open lumbar discectomy, ICU: Intensive Care Unit, CNY: Chinese Yuan)

**Table 3:** Comparison of pediatric and adult lumbar disc herniation in specific aspects.

	Pediatric LDH	Adult LDH
<b>Etiology</b>	Trauma from sport injuries , decreased range of motion (ROM), poor conditioning, excessive or repetitive axial loading and improper technique	Degenerative changes due to aging
	Heavy lifting and athletic activities that result in falls	Family history
	Engaging in new training proposes can exacerbate the prevailing lesions of the discs.	Male gender
	Genetic factors	Age of 30-50 years
<b>Symptoms</b>	Low back pain and radiculopathy of lower extremities	Heavy lifting or twisting
	Neurological symptoms such as numbness and weakness are relatively rare	Stressful occupation
	Positive SLR test	Lower income
<b>Treatments</b>	Conservative treatment is generally recommended as the first-line treatment for LDH in pediatric population without neurological deficits.	Cigarette smoking
	Surgical management of lumbar disk herniation interferes in patients who have failed nonsurgical therapy and in patients with progressive neurologic deficit or debilitating pain.	Major accidents
<b>Outcomes</b>	Compared outcome of conservative treatment with surgical treatment has found that surgical treatment lead to a significant better outcome than conservative treatment	Low back pain followed by sciatica.
	Reports are found on narrowing of disc space, foraminal stenosis and adjacent disc degeneration or recurrent disc herniation from few months to several years after surgery, the clinical outcome was not affected accordingly.	Paresthesia, Motor weakness, reflex changes, atrophy, or sensory loss
	Long-term follow up is recommended	Positive SLR test
		Conservative is generally recommended as the first-line treatment.
		Surgery may be recommended if there is unbearable pain, non-responsive to medical management, unacceptable or progressive weakness, evidence of spinal cord compression, and/or bowel or bladder concerns.
		Conservative treatment responds to approximately 80% of patients.
		It has been shown that between 85 and 90% of surgically treated and nonsurgically treated patients were asymptomatic at 4 years. Less than 2% of both groups were symptomatic at 10 years.
		Long-term follow up is recommended

### Fusion

Few reports in the literature concern the use of spinal fusion on pediatric LDH to relieve symptoms by restoring stability. Majority of literature agree that fusion should not be performed routinely since there is no specific improve outcome or decrease the recurrence rate of disk herniation. Therefore, fusion procedure increases operative

time, blood loss, and cost of surgery without additional benefits [2,3,4].

However, the mostly accepted indications for spinal fusion are limited to; [9] disc herniation with spondylolisthesis or clear indications of instability, [10] multiple level laminectomy, [11] incompetence of the facet joints due to either degenerative, congenital oriatrogenic causes [2,3,4].

After the initial treatments longer follow-up is necessary for PLDH because the chances of recurrence or the involvement of adjacent levels cannot be denied.

The following table compares the surgical results regarding different operation methods used in China (Table 2).

### Postoperative complications-

Early post-operative complications found in pediatric patients include wound hematoma and delayed wound healing. Post-operative infection such as wound infection and discitis secondary to lumbar spine surgery is rare in children and adolescents [2,8].

Although there are reports found on narrowing of disc space, foraminal stenosis and adjacent disc degeneration or recurrent disc herniation from few months to several years after surgery, the clinical outcome was not affected accordingly [2].

Relevant to the distinct information of the paper, following table (Table 3) shows the specifications of pediatric LDH compared with adults' population with this disease.

## Conclusion

Lumbar disk herniation in the pediatric patients is a relatively rare clinical entity as it constituted 0.5% to 6.8% of all patients hospitalized for LDH. A relevant medical history, directed physical examination and appropriate imaging studies are helpful in diagnosing PLDH. Symptomatic disk herniation is mostly reported after trauma or sports related injury in 30%-60% of children and adolescents LDH population where the symptoms appear within a few hours of the injury. New onset low back pain and lower extremity radiculopathy is mostly significant. MRI is the standard imaging technique for LDH, however, preoperative CT scan is recommended to assess for the presence of a bony fragment, as seen with apophyseal fracture.

The segmental distribution of disk herniation is seen in L4-L5 and L5-S1 levels in over 50% of all disc herniations while majority of disk herniations are contained and paracentral. Conservative treatment is generally recommended as the first-line treatment for LDH in pediatric population without neurological defects. It consists of bed rest, medication, physical therapy and limitation of physical activity. Surgical management of lumbar disk herniation interferes in patients who have failed nonsurgical therapy and in patients with progressive neurologic deficit or debilitating pain. Modalities of surgical consist of percutaneous endoscopic lumbar discectomy (PELD) and open discectomy. Fusion of vertebrae is not essential. However, long term follow-up is necessary for because the chances of recurrence or the involvement of adjacent levels cannot be denied.

## References

- Dang L, Chen Z, Liu X, Guo Z, Qi Q, Li W, et al. Lumbar Disk Herniation in Children and Adolescents: The Significance of Configurations of the Lumbar Spine. *Neurosurgery*. 2015; 77: 954-959.
- Dang L, Liu Z. A review of current treatment for lumbar disc herniation in children and adolescents. *Eur Spine J*. 2010; 19: 205-214.
- Jonathan RS, John MK, Mislow, Arthur LD, Mark RP. *Pediatric disk disease*. *Neurosurg Clin N Am*. 2007; 18: 659-667.
- Kumar R, Kumar V, Das NK, Behari S, Mahapatra AK. Adolescent lumbar disc disease: findings and outcome. *Childs Nerv Syst*. 2007; 23: 1295-1299
- Lavelle WF, Bianco A, Mason R, Betz RR, Albanese SA. *Pediatric Disk Herniation*. *J Am Acad Orthop Surg*. 2011; 19: 649-656.
- Kaveh Haddadi. *Pediatric Lumbar Disc Herniation: A review of manifestations, diagnosis and management*. *J Pediatr Rev*. 2016; 4: e4725.
- Wang H, Cheng J, Xiao H, Li C, Zhou Y. Adolescent lumbar disc herniation: Experience from a large minimally invasive treatment centre for lumbar degenerative disease in Chongqing, China, clinical neurology and neurosurgery. 2013; 115: 1415-1419.
- Wang X, Zeng J, Nie H, Chen G, Li Z, Jiang H. Percutaneous endoscopic interlaminar discectomy for pediatric lumbar disc herniation. *Childs Nerv Syst*. 2014; 30: 897-902.
- Rattan KN, Arushi Agarwal, Ankur Dhiman, Ananta Rattan. Congenital Lumbar Hernia: A 15-Year Experience at a Single Tertiary Centre. *International Journal of Pediatrics*. 2016; 4.
- Yang S, Werner BC, Singla A, Abel MF. Low Back Pain in Adolescents: A 1-Year Analysis of Eventual Diagnoses. *J Pediatr Orthop*. 2017; 37.
- Sharma A, Pandey A, Rawat J, Ahmed I, Wakhlu A, Kureel SN. Congenital lumbar hernia: 20 years' single centre experience. *J Paediatr Child Health*. 2012; 48: 1001-1003.
- Satoshi Tsutsumi, Yukimasa Yasumoto, Masanori Ito. Idiopathic intervertebral disk calcification in childhood: a case report and review of literature. *Childs Nerv Syst*. 2011; 27: 1045-1051.
- Erica M Giblin, Gary M Hochheiser. Thoracic Disk Herniation Resulting in Acutely Progressing Paraplegia in a Pediatric Patient. *Pediatric Emergency Care*. 2008; 24.
- Karmani S, Ember T, Davenport R. Congenital Lumbar Hernias: A Case Report. *J Pediatr Surg*. 2002; 37: 921-922.
- James E Tomlinson, Nigel W Gummerson. *Paediatric spinal conditions, Surgery (Oxford)*. 2017; 35: 39-47.
- Humphreys SC, Eck JC. Clinical Evaluation and Treatment Options for Herniated Lumbar Disc. *Am Fam Physician*. 1999; 59: 575-582.
- Garrido E. Lumbar disc herniation in the pediatric patient. *Neurosurg Clin N Am*. 1993; 4: 149-152.
- Billot C, Desgrappes Y, Bensahel H. Lumbar disc herniation in childhood (author's transl). *Rev Chir Orthop Reparatrice Appar Mot*. 1980; 66: 43-46.
- Lavelle WF, Bianco A, Mason R, Betz RR, Albanese SA. Pediatric disk herniation. *J Am Acad Orthop Surg*. 2011; 19: 649-656.
- John SD, Allbery S. Disk degenerative disease in childhood: Scheuermann's disease, Schmorl's nodes, and the limbus vertebra: MRI findings in 12 patients. *Pediatr Radiol*. 1998; 28: 334-338.
- Mayer HM, Brock M. Percutaneous discectomy in the treatment of pediatric lumbar disk disease. *Surg Neurol*. 1988; 29: 311-314.
- Dewing CB, Provencher MT, Riffenburgh RH, Kerr S, Manos RE. The outcomes of lumbar microdiscectomy in a young, active population: correlation by herniation type and level. *Spine (Phila Pa 1976)*. 2008; 33: 33-38.
- Roberts MP. Lumbar disc herniation. Standard approach. *Neurosurg Clin N Am*. 1993; 4: 91-99.
- Onik GM. Percutaneous discectomy in the treatment of herniated lumbar disks. *Neuroimaging Clin N Am*. 2000; 10: 597-607.
- Ortega-Martínez M, Cabezudo JM, Fernández-Portales I, Gómez-Perals L, Bernal-García LM. Calcified disc herniation in childhood. *Neurocirugía (Astur)*. 2006; 17: 333-338.
- Okada E, Matsumoto M, Fujiwara H, Toyama Y. Disc degeneration of cervical spine on MRI in patients with lumbar disc herniation: comparison study with asymptomatic volunteers. *Eur Spine J*. 2011; 20: 585-591.
- da Silva V, Beyeler F, Mumenthaler M, Robert F, Vassella F. Lumbar intervertebral disc herniation in children. A report of 16 cases (author's transl). *77; 34: 405-408*.
- Kotilainen E. Diagnosis and treatment of vertebral disc herniation. *Duodecim*. 1995; 111: 2078-2083.
- Zhai XJ, Bi DW, Fu H, Zu G. Treatment of lumbar disc herniation with lateral recess stenosis by microendoscopic discectomy. *Zhongguo Gu Shang*. 2008; 21:120-121.
- Liu C, Zhou Y. Percutaneous Endoscopic Lumbar Discectomy and Minimally Invasive Transforaminal Lumbar Interbody Fusion for Recurrent Lumbar Disk Herniation. *World Neurosurg*. 2017; 98: 14-20.
- Yao Y, Zhang H, Wu J, Liu H, Zhang Z, Tang Y, et al. Comparison of Three Minimally Invasive Spine Surgery Methods for Revision Surgery for Recurrent Herniation After Percutaneous Endoscopic Lumbar Discectomy. *World Neurosurg*. 2017; 100: 641-647.
- Keorochana G, Setrkraising K, Woratanarat P, Arirachakaran A, Kongtharvonskul J. Clinical outcomes after minimally invasive transforaminal lumbar interbody fusion and lateral lumbar interbody fusion for treatment of degenerative lumbar disease: a systematic review and meta-analysis. *Neurosurg Rev*. 2018; 41: 755-770.
- Kovac D, Negovetić L, Vukić M, Klanfar Z, Jajić Z. Surgical treatment of lumbar disc hernias in athletes. *Reumatizam*. 1998; 46: 35-41.

34. Ozgen S, Konya D, Toktas OZ, Dacinar A, Ozek MM. Lumbar disc herniation in adolescence, *Pediatr Neurosurg*. 2007; 43: 77-81.
35. Mahsa Sedighi, Ali Haghnegahdar. Lumbar Disk Herniation Surgery: Outcome and Predictors. *Global Spine J*. 2014; 4: 233-244.
36. Williams RW. Lumbar disc disease. Microdiscectomy. *Neurosurg Clin N Am*. 1993; 4: 101-108.
37. Reina EG, Calonge ER, Heriot RP. Transdural lumbar disc herniation, *Spine (Phila Pa 1976)*. 1994; 19: 617-619.
38. Eddy Garrido. Lumbar Disc Herniation in the Pediatric Patient, *Neurosurgery Clinics of North America*. 1993; 4: 149-152.