

Parapharyngeal Space Myofibroma: A
Case Report and Review of the LiteratureAlain Sabri¹, Zeina Korban¹, Samer Abou Rizk² and Randa Al Barazi^{2*}¹Otolaryngology Head and Neck Surgery, Cleveland Clinic Abu Dhabi, UAE²Department of Otolaryngology – Head and Neck Surgery, American University of Beirut Medical, Lebanon

Article Information

Received date: Aug 18, 2015

Accepted date: Oct 15, 2015

Published date: Nov 02, 2015

*Corresponding author

Randa Al Barazi, Department of
Otolaryngology – Head and Neck
SurgeryAmerican University of Beirut Medical
Center, PO Box: 11-0236, Riad el Solh,
Beirut 1107 2020
Beirut– Lebanon, Email: ra110@aub.
edu.lbDistributed under Creative Commons
CC-BY 4.0Keywords Myofibroma; Parapharyngeal
space; Modified radical neck dissection

Abstract

Myofibroma is a rare, benign tumor of soft tissues representing the most common fibrous tumor of infancy. It has a wide array of presentations, most commonly in the head and neck region, constituting unique diagnostic and therapeutic challenges. Myofibromas have typically a predilection for the mandible, and parapharyngeal involvement is extremely rare. This is the case of a six-year-old girl with an unusual presentation of myofibroma in the right parapharyngeal space compressing on the trachea and causing stridor and dyspnea. The patient was treated surgically and the mass was excised due to mass effect. She presented several months later with recurrence of the mass and the patient had to undergo a right modified radical neck dissection for better exposure and access of the tumor. This is the second case of parapharyngeal myofibroma reported in the literature and the first to have been excised using a modified radical neck dissection approach.

Introduction

Myofibroma is a rare, benign, nodular tumor of soft tissues, bones or internal organs [1]. It represents the most common fibrous tumor of infancy [2]. Presentation varies from a solitary form that predominates in males with a predilection in the head and neck region constituting the most common form; and a multicentric form, commonly found in bone or viscera. Generalized myofibromatosis is associated with visceral involvement. Diagnosis is challenging attributed to the variability in symptomatology. Genetic inheritance of variable penetrance can be associated but most of the reported cases are idiopathic in nature. Approximately 90% of cases present before 2 years of age [3].

Myofibromas can regress without intervention and conservative treatment is the choice. However, primary treatment for symptomatic lesions is surgical excision. Cases involving the mandible, tongue, lips, cheek, maxilla, palate and floor of mouth have been reported. However, parapharyngeal space involvement is extremely rare. To our knowledge, only one case of parapharyngeal myofibroma has been previously reported in the literature [4]. We hereby present the case of a six-year-old girl with a very rare presentation of a recurrent myofibroma due to its unusual location in the parapharyngeal space requiring a modified radical neck dissection for better access of the lesion in order to achieve complete surgical excision.

Case Report

This is the case of a six-year-old girl, born by C-section to non-consanguineous parents presented at the age of two with a right neck mass, progressively increasing in size, non-tender with no associated skin changes. The mass is located in the anterior neck triangle approximately 5x5 cm in size leading to stridor and dyspnea with tracheal compression (Figures 2,3).

She received multiple courses of antibiotics with no subjective improvement. Biopsy done revealed the presence of fibromatosis. Few months later, she underwent excision of the parapharyngeal mass with neck exploration.

Intraoperatively, the mass was found to be encasing the carotid artery and adherent to the vagus nerve. The carotid artery and the vagus nerve were dissected off the mass.

Dissection extended all the way medially to the retropharyngeal space. Pathology was consistent with myofibromatosis. The patient presented seven months later with a recurrent right neck mass. Follow-up MRI revealed a 4.3x2.7x5.6 cm bi-lobed mass, encasing the right common carotid artery and sternocleidomastoid muscle. Patient underwent a right modified radical neck dissection with excision of the mass. Intraoperatively, the contents of the right posterior triangle, right internal jugular vein and sternocleidomastoid were removed, sparing the right vagus nerve and subclavian artery and vein (Figures 1,4). The pathology was consistent with recurrent myofibroma with positive margins and negative lymph nodes. She received several cycles of adjuvant chemotherapy. She is now twelve-years-old, clinically stable and her last MRI showed no recurrence.

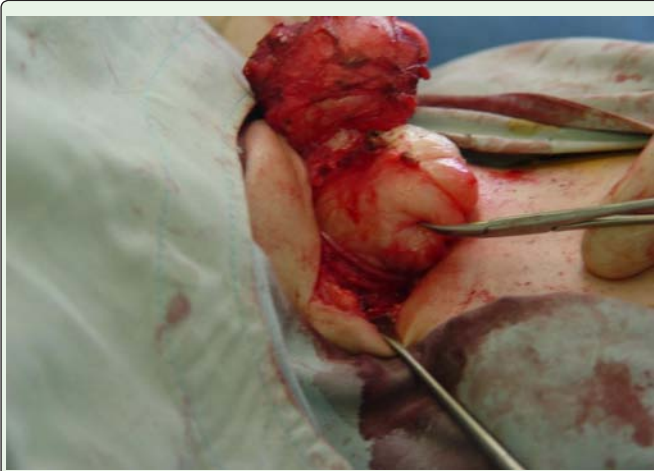


Figure 1: Intra-operative picture of the mass.

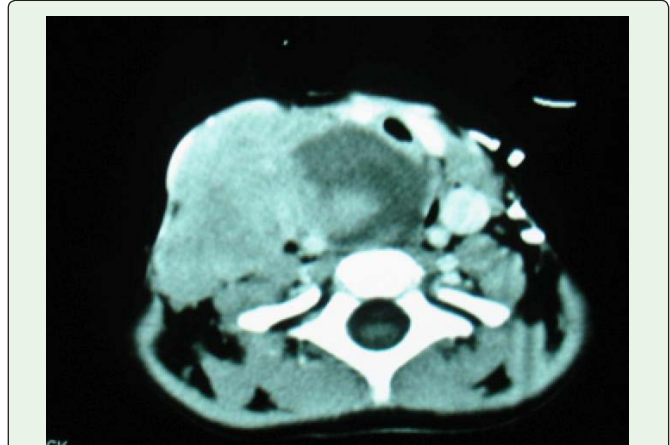

Figure 3: CT scan: axial cut showing the extension of the mass into the parapharyngeal space.

Discussion

Myofibroma was first described as congenital fibrosarcoma in 1951, by William and Schrum [5]. Stout later described this entity in 1954 as a form of congenital multicentric fibroblastic proliferation “congenital generalized fibromatosis” [6]. Based on its histological description, Chung and Enzinger chose the name “infantile myofibromatosis” [3]. Smith et al. used the term “myofibroma” to describe the solitary form of these lesions [7].

Myofibromas are benign mesenchymal lesions that can typically arise as single or multiple nodules with possible visceral involvement in up to 35% of multicentric cases [8]. Prognosis depends on the anatomical location with the greatest risk arising from lesions that have visceral involvement. This condition can have up to 76% mortality rate, typically resulting from gastrointestinal or cardiopulmonary complications [2,3]. Kauffman divided this lesion into two types:

those that affect the skin, subcutaneous tissue, or skeleton and tend to have a good prognosis, and those with a poorer prognosis that involve the soft tissue, muscles, bone or internal organs. Grossly, they appear as rubbery, firm, hard and slow-growing masses. Due to its vasculature, these lesions may resemble hemangiomas. The etiology is currently unclear. Some authors advocate an autosomal dominant [9-11] or autosomal recessive trait with variable penetrance [12,13]. Maternal mesenchymal stem cells transferred during pregnancy have been hypothesized to play a role. In addition, maternal estrogen has shown to contribute to the development of myofibromatosis [14]. This tumor is challenging to diagnose attributed to its slow-growing, nodular swelling.

The distribution is predominantly on the head and neck region, with a predilection for the mandible. The tongue, buccal mucosa, lip and vestibule can also be involved.

Histologic analysis reveals the presence of myofibroblasts with ovoid nuclei (spindle-shaped cells) in the periphery, whereas less differentiated, hemangiopericytoma-like cells occupy the central portion giving its characteristic-zoning pattern [3,14,15]. Atypical mitotic figures are usually not seen. A variety of stains are available.

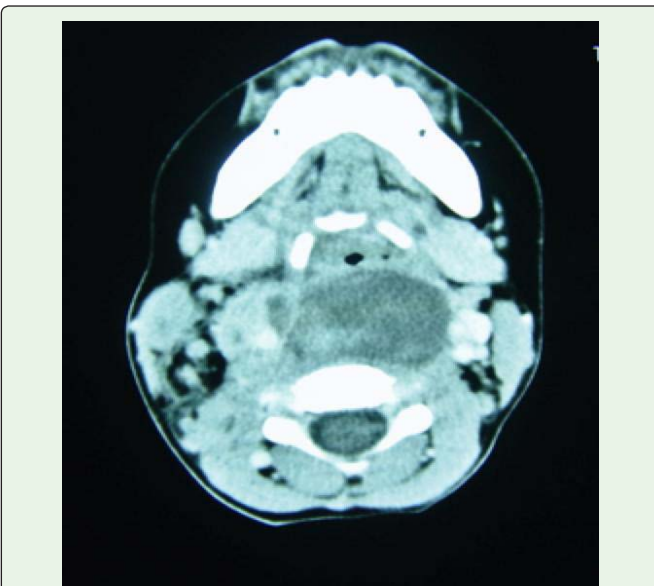


Figure 2: CT scan: axial cut showing the extension of the mass into the parapharyngeal space.

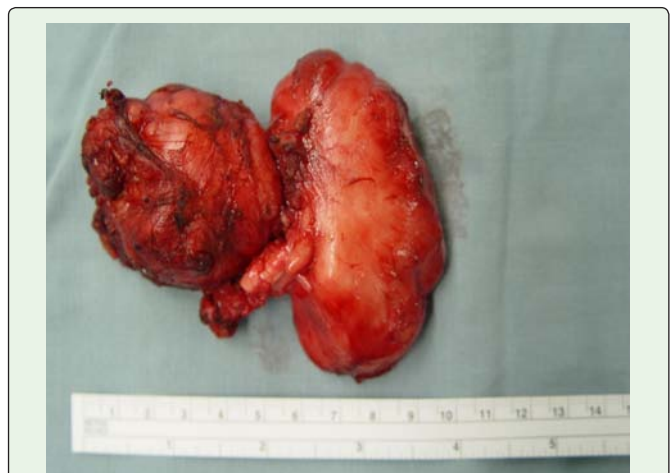


Figure 4: Gross specimen after surgical excision.

Myofibromas typically stain positive for smooth muscle actin (SMA) and vimentin; but negative for S-100 protein, keratin, CD99, GFAP and muscle markers (muscle specific actin, desmin, myogenin) [16,17].

Definite histopathological diagnosis is complex because of its similarity to other spindle cell lesions. Many authors believe that hemangiopericytoma and infantile myofibromatosis represent different stages of maturation of the same entity [15]. Tumors of nerve tissue origin, neurofibromas, leiomyomas and malignant lesions, such as fibrosarcomas, leiomyosarcomas, metastatic neuroblastoma must be considered in the differential diagnosis [18]. In addition, it must also be differentiated from rhabdomyosarcoma; nonetheless, the latter lacks the characteristic-zoning phenomenon.

Treatment depends on systemic and local manifestations that can ensue, and on the clinical presentation. Typically, myofibromas regress spontaneously without the need of intervention and asymptomatic cases can be managed conservatively with a "wait and see" approach. Surgical excision is the mainstay of treatment in symptomatic lesions affecting vital organ functions, with recurrence rates up to 10% [2,3]. This can be attributed to incomplete surgical excision or difficult surgical access. Due to those reasons, a modified radical neck dissection was necessary in our case for better intra-operative exposure of the lesion. Garcia et al. described a parapharyngeal myofibroma that was approached through a transoral "double Y" incision of the soft palate, resecting the tumor after blunt dissection and exposure [4]. This difference could be due to the different extension of the lesions.

Radiation, alpha interferon A, local corticosteroid injections, or chemotherapy with vincristine, actinomycin D, and cyclophosphamide have also been described in the management of myofibromas [19-21], though limited by the associated side effects that can ensue.

Conclusion

Our case represents a very rare presentation of myofibroma due to its location in the parapharyngeal space. This is the first report of the surgical removal of a parapharyngeal myofibroma using a modified radical neck dissection. In summary, although extremely rare, it is crucial to have this diagnosis in mind in a child presenting with a soft tissue tumor. Their ability to obstruct and involve vital structures emphasizes the importance of early and accurate diagnosis and intervention.

References

- Nishioka K, Seguchi T, Yamamura Y, Tatumura M, Sou H, Gondo T, et al. Infantile myofibromatosis identified by fetal ultrasound. *Br J Dermatol*. 1999; 140: 539-541.
- Wiswell TE, Davis J, Cunningham BE, Solenberger R, Thomas PJ. Infantile myofibromatosis: the most common fibrous tumor of infancy. *J Pediatr Surg*. 1988; 23: 315-318.
- Chung EB, Enzinger FM. Infantile myofibromatosis. *Cancer*. 1981; 48: 1807-1818.
- Garcia-Perla A, Belmonte-Caro R, Infante-Cossio P, Muñoz-Ramos M, Esteban-Ortega F. Upper airway distress due to an oropharyngeal infantile myofibroma. *J Craniomaxillofac Surg*. 2012; 40: e112-114.
- Williams Jo, Schrum D. Congenital fibrosarcoma; report of a case in a newborn infant. *AMA Arch Pathol*. 1951; 51: 548-552.
- Stout AP. Juvenile fibromatoses. *Cancer*. 1954; 7: 953-978.
- Smith KJ, Skelton HG, Barrett TL, Lupton GP, Graham JH. Cutaneous myofibroma. *Mod Pathol*. 1989; 2: 603-609.
- Roggli VL, Kim HS, Hawkins E. Congenital generalized fibromatosis with visceral involvement. A case report. *Cancer*. 1980; 45: 954-960.
- Ikediobi NI, Iyengar V, Hwang L, Collins WE, Metry DW. Infantile myofibromatosis: support for autosomal dominant inheritance. *J Am Acad Dermatol*. 2003; 49: S148-150.
- Bracko M, Cindro L, Golouh R. Familial occurrence of infantile myofibromatosis. *Cancer*. 1992; 69: 1294-1299.
- Zand DJ, Huff D, Everman D, Russell K, Saitta S, McDonald-McGinn D, et al. Autosomal dominant inheritance of infantile myofibromatosis. *Am J Med Genet A*. 2004; 126A: 261-266.
- Baird PA, Worth AJ. Congenital generalized fibromatosis: an autosomal recessive condition? *Clin Genet*. 1976; 9: 488-494.
- Salamah MM, Hammoudi SM, Sadi AR. Infantile myofibromatosis. *J Pediatr Surg*. 1988; 23: 975-977.
- Gopal M, Chahal G, Al-Rifai Z, Eradi B, Ninan G, Nour S. Infantile myofibromatosis. *Pediatr Surg Int*. 2008; 24: 287-291.
- Mentzel T, Calonje E, Nascimento AG, Fletcher CD. Infantile hemangiopericytoma versus infantile myofibromatosis. Study of a series suggesting a continuous spectrum of infantile myofibroblastic lesions. *Am J Surg Pathol*. 1994; 18: 922-930.
- Mynatt CJ, Feldman KA, Thompson LD. Orbital infantile myofibroma: a case report and clinicopathologic review of 24 cases from the literature. *Head Neck Pathol*. 2011; 5: 205-215.
- Brasileiro BF, Martins-Filho PR, Piva MR, Da Silva LC, Nonaka CF, Miguel MC. Myofibroma of the oral cavity. A rare spindle cell neoplasm. *Med Oral Patol Oral Cir Bucal*. 2010; 15: e596-600.
- Lopes RN, Alves Fde A, Rocha AC, Suassuna TM, Kowalski LP, de Castro JF, et al. Head and neck solitary infantile myofibroma: Clinicopathological and immunohistochemical features of a case series. *Acta Histochem*. 2015; 117: 431-436.
- Gandhi MM, Nathan PC, Weitzman S, Levitt GA. Successful treatment of life-threatening generalized infantile myofibromatosis using low-dose chemotherapy. *J Pediatr Hematol Oncol*. 2003; 25: 750-754.
- Savaşan S, Fulgenzi LA, Rabah R, Mohamed AN, Ravindranath Y. Generalized infantile myofibromatosis in a patient with Turner's syndrome: a trial of interferon-alpha. *J Pediatr*. 1998; 133: 694-696.
- Schurr P, Mouldsdale W. Infantile myofibroma: a case report and review of the literature. *Adv Neonatal Care*. 2008; 8: 13-20.