

## Seminoma in an Undescended Testis

Sayantan Bose, Shreya Sengupta\* and Ramanuj Mukherjee

Department of Surgery, R. G. Kar Medical College, India

## Article Information

Received date: Nov 22, 2017

Accepted date: Dec 14, 2017

Published date: Dec 20, 2017

## \*Corresponding author

Shreya Sengupta, Department of Surgery, R. G. Kar Medical College, 10, Baroda Avenue, Baishnabghata, Kolkata-700084, India,  
Tel: +918617252967;  
Email: shreya.95edcn@gmail.com

**Distributed under** Creative Commons CC-BY 4.0

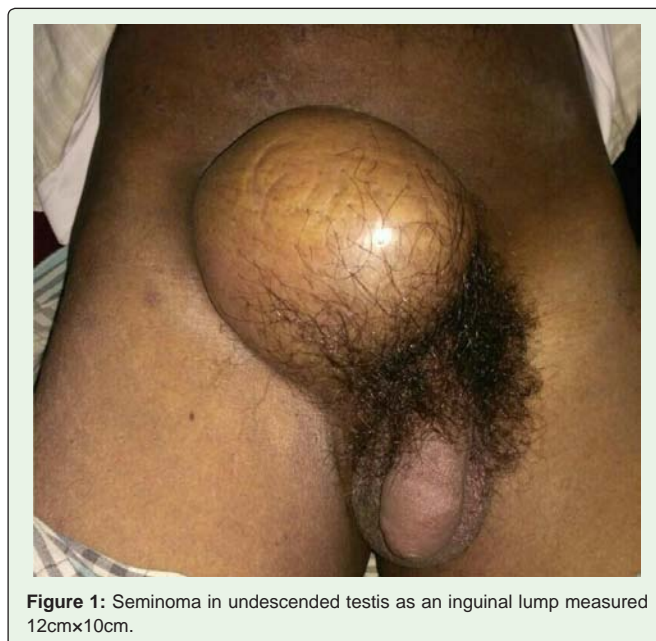
**Keywords** Seminoma; Undescended Testis; Complications of Undescended Testis; Cryptorchidism

## Abstract

Seminoma in undescended testis may present as an inguinal lump. We present a case of a 32 year old gentleman who presented with a tender right inguinal lump diagnosed to be as Seminoma in an undescended testis. Serological and imaging studies were done for staging. PET-CT scan showed metastasis to retroperitoneal lymph nodes. High radicle orchidectomy with retroperitoneal lymph node dissection was done followed by radiotherapy and chemotherapy.

## Case Study

A 32 year old gentleman presented with a right sided inguinal swelling for last 2 months. It was painless and non-reducible. On examination, the lump measured 12cm×10cm (Figure 1), was hard, non-tender, non-reducible, non-compressible, free from skin and relatively immobile. His right scrotum was empty and rugosity was not well formed. On enquiry he said that his right scrotum had been like that since birth. There was no history of infertility. Features of distant metastasis could not be clinically extracted. He underwent through CT and PET-CT scan that showed retroperitoneal lymph node metastasis of size <2cm. There were no other sites of metastasis. A high radicle orchidectomy with retroperitoneal lymph node dissection was performed. Disease was staged to be at stage IIa. Histopathology showed it was a classical type of seminoma. The patient was referred to oncology department where he received 2 cycles of radiotherapy and 4 cycles of cisplatin and etoposide.



**Figure 1:** Seminoma in undescended testis as an inguinal lump measured 12cm×10cm.

## Discussion

Undescended testis is a very common congenital anomaly present in about 1-4.5% of newborn males with a higher incidence in preterm males (30-45%) [1,2]. But testes may descend into the scrotum in 75% of full-term neonates and in 90% of premature newborn boys in infancy, and the incidence decreases to 0.8-1.2% at 1 year of age [3-5]. Other than infertility, associated inguinal hernia and torsion, malignant change in undescended testis is a common complication that we come across [1,5]. The risk for cancer is 35 to 48 times higher in patients with undescended testes compared to the overall population. About 10% of all testicular cancers are associated with cryptorchidism, with the risk being highest with abdominal testis [5]. Testicular tumours have highest incidence in the age group of 15-40

years [6]. 95% of testicular tumours are germ cell tumours with half of them being seminoma. 85% of these are classical type and rest are anaplastic or spermatocytic. Seminoma is one the curable cancers, with cure rates nearing 100% even in stage II disease with surgery and radiotherapy [7].

## References

1. Ashley RA, Barthold JS, Kolon TF. Cryptorchidism: pathogenesis, diagnosis, treatment and prognosis. *The Urologic Clinics of North America*. 2010; 37: 183-193.
2. Hutson JM, Balic A, Nation T, Southwell B. Cryptorchidism. *Seminars Pediatrics Surgery*. 2010; 19: 215-224.
3. Elder JS. The undescended testis. Hormonal and surgical management. *Surgical Clinics of North America*. 1988; 68: 983-1005.
4. Khatwa UA, Menon PS. Management of undescended testis. *Indian Journal of Pediatrics*. 2000; 67: 449-454.
5. Leissner J, Filipas D, Wolf HK, Fisch M. The undescended testis: considerations and impact on fertility. *BJU International*. 1999; 83: 885-891.
6. Chia VM, Quraishi SM, Devesa SS, Purdue MP, Cook MB, McGlynn KA. International trends in the incidence of testicular cancer, 1973-2002. *Cancer Epidemiol Biomarkers Prev*. 2010; 19: 1151-1159.
7. Woods M, Castle EP, Stroup SP, et al: Testis neoplasms. *American Urological Association*. 2015.