

Supercutaneous Locking Platefixation in
Orthopedics : A Systematic Review Based
on Clinical StudiesDing Xu¹, Jia Wu², Yi-Heng Chen^{3,4}, Weijun Guo^{3,4} and Peng Luo^{3,4*}¹Department of Orthopedics and Traumatology, Shangyu people's hospital of shaoxing city, China²Key Laboratory for Laboratory Medicine, Wenzhou Medical University, China³Department of Orthopedic Trauma Surgery, The second affiliated hospital and Yuying Children's hospital of Wenzhou Medical University, China⁴Zhejiang provincial key lab of orthopaedics, China

Article Information

Received date: Sep 11, 2017

Accepted date: Nov 30, 2017

Published date: Dec 05, 2017

*Corresponding author

Peng Luo, Department of Orthopedics and Trauma Surgery, The second affiliated hospital and yuying Children's hospital of Wenzhou Medical University, China, Tel: 086+0577-88002810; Email: luopeng19850019@163.com

Distributed under Creative Commons CC-BY 4.0

Keywords Locked plating; External fixator; Supercutaneous; Orthopedics

Abstract

Background: This article is a systematic review of the published literature about the application of locked plating as an external fixator in treating orthopedic disorders.

Material & Methods: We searched the PubMed, Ovid Medline, Embase, Science Direct, Cochrane Library databases to retrieve the relevant studies. Studies published in English and Chinese, which described the clinical use of locked plate in treating orthopedic disorders were included. With regards to the articles written by the same authors or departments are treated with caution because the patients may overlap among these articles. Only the latest published study should be selected if any overlapping patients may exist among the articles. Exclusive criteria were as follows: (1) pure biomedical studies; (2) duplicate studies; (3) reviews, letters and comments?; (4) language rather than English and Chinese; and (5) full-text of the article cannot be obtained.

Results: The electronic search strategy revealed 735 studies and 2 studies were identified as relevant through references manual search. Finally, 22 studies were included in this systematic review. The clinical studies showed that external locked plating as an external fixation to manage orthopedic diseases had a satisfactory functional outcome, union rate and low complication rate.

Conclusion: Based on the clinical studies, locked plating as an external fixator to manage orthopedic disorders can be considered as a safe and successful procedure. However, there is unconvincing evidence that it is superior to standard techniques with regards to clinical and functional outcomes. More and well-designed studies about this technique should be carried out further.

Introduction

Trauma is a leading cause of death under the age of 40 years and the promptness of care is critical to deceased patients' mortality and disability [1]. In a majority of trauma cases, particularly those who present skin or neurovascular structures in danger, undesirable alignment, and comminuted fractures, then Open Reduction and Internal Fixation (ORIF) is used to stabilize the fracture [2]. Stabilization of fractures with plates was widely adopted after the appearance of dynamic compression plates that enabled inter fragmentary compression to achieve absolute stability and primary bone healing. Dynamic compression plates have to be pressed directly to the bone, which may cause a disturbance in the blood supply. Besides, open reduction and internal fixation often requires extensive soft-tissue which may be associated with complications such as soft tissue necrosis and infection and nonunion [3].

External fixation has seen renewal in modern trauma management as a temporary fixator or definitive fixation for the high-energy injury, especially for open fractures. Although external fixators were easy to handle, many complications such as loosening and infection, delayed fracture healing, or nonunions, have been observed [4]. Moreover, most external fixators are bulky and cumbersome for the patients, which may impact the life quality of patients.

The introduction of locking plates supported the desire for biologic plate osteosynthesis. The angular stable anchoring of screws in the plate, which overcomes the shortcoming of dynamic compression plates, eliminated the need for plate compression against the bone. Locking plates depend on secondary bone healing with callus formation through increased flexibility in stabilization [5]. In addition, they do not rely on the screw purchase in bone, as a result, are more advantageous in comminuted and osteoporotic fractures [6].

Kloen [7] et al. Were the first to introduce the use of a locked compression plate as external fixation for treating chronic posttraumatic problems and they called this method as the "supercutaneous plating technique." After that, it has been an increasing interest in this technique because of the angular stability from the locking-head mechanism and less irritation compared with traditional

external fixator. A number of authors used supercutaneous plating technique to deal with orthopedic diseases including infection, open or close fracture, and even bone defect [8-10]. To our knowledge, there is no systematic review on the clinical application of the supercutaneous locking plate fixation in orthopedics. Thus, we systematically reviewed the published literature on locking plate used as an external fixator to treat orthopedic disorders.

Material & Methods

Search strategy

This systematic review was conducted according to the Preferred Reporting Items for Systematic Reviews and Meta-analysis (PRISMA) statement [11]. Comprehensive databases including PubMed, Ovid Medline, Embase, Science direct, Cochrane Library have been used to identify the relevant studies published up to 23rd February, 2017. The following search terms were employed: ((((((external fixation) OR external fixator)) AND (((locking plate) OR locking compression plate) OR LCP) OR locked plate) OR locked compression plate))) OR ((Supercutaneous plating) OR Supercutaneous technique))) AND ((tibia) OR tibial fracture). We also manually searched the references of selective articles to identify additional potentially relevant studies.

Selection criteria

All studies described the clinical use of locked plate in treating orthopedic disorders were included. With regards to the articles written by the same authors or departments are treated with caution because the patients may overlap among these articles. Only the latest published study should be selected if any overlapping patients may exist among the articles. Exclusive criteria were as follows: (1) pure biomedical studies; (2) duplicate studies; (3) reviews, letters and comments; (4) language rather than English and Chinese; and (5) full-text of the article cannot be obtained.

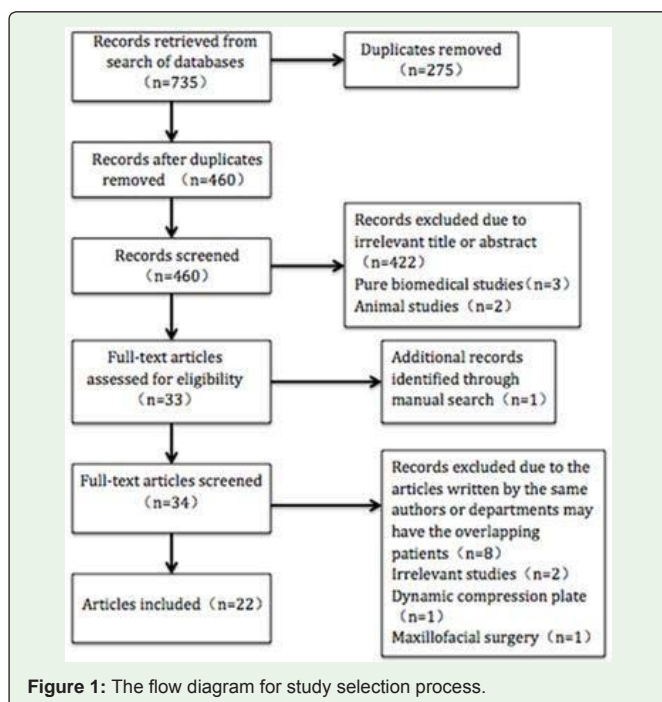


Figure 1: The flow diagram for study selection process.

Data extraction and quality assessment

Two independent reviewers screened the titles and abstracts. Studies meeting the selection criteria were retrieved for full-text evaluation. Any discrepancy was resolved by consensus. Remnant studies were assessed according to the Oxford Centre for Evidence-Based Medicine. The data including first author's name, publication year, country, study design, level of evidence, inclusive population, patient number, gender, age, role of external locked plate and data in terms of clinical features and outcomes were extracted from each included study in standardized forms using Microsoft Excel. Data on clinical outcomes and complications were extracted from each study so that pooled results could be reported, but formal data synthesis was not possible due to the heterogeneity of the studies.

Results

A total of 735 studies were found through the electronic searching engines, and one study was identified as relevant through references manual search. Finally, 22 studies were included in this systematic review. The study selection process was shown in figure 1. The details of clinical studies were summarized in tables 1-3.

Definitive Fixation or Temporary Fixation

Seventeen studies [7-10,12-24] utilized the locked plate as the definitive fixator: One study [8] was used for treating large distal tibial defect; Three studies [12-14] were used for treating calcaneal fractures; Ten [9,15-21,24,25] were used for open or closed tibial fracture; There were used for Chronic posttraumatic infection [10,23,26]. Two studies [27,28] used the locked plate as the temporary fixation, all of them were used for fixing tibial fractures [15,27]. Three studies [7,25,29] were utilized the locked plate not only as a temporary fixation, but also as a definitive fixation: Two [7,25] were used for chronic posttraumatic infection and one was used for tibial fracture [29].

Bone defect

In Apivatthakakul [8] et al's study, 29 years old patients who sustained a Gustilo type IIIB open distal tibial fracture with 9 cm×15 cm of soft-tissue injury and 8.4 cm segmental bone defect was fixed by a locked plate as an external fixator to maintain the alignment of lower limb. Four weeks after healing of the flap wound, the bone transport procedure was performed. A small Wagner lengthening device was applied on the anterior surface of the tibia for distraction osteogenesis after 7days later when corticotomy was under taken. The total distraction time was 96 days with 0.5 mm/day in the first 3 weeks and 1 mm/day 3 weeks later and the total external fixation time was 10 months. The man had an excellent functional outcome, satisfactory ankle movement, and return to normal daily living and work.

Chronic posttraumatic infection

Five studies [7,10,23,25,26] reported used supercutaneous locking plate technique for treating chronic posttraumatic infection. Three of them mentioned that they used it to deal with infected clavicle fracture (n=3) [7,23,26]. Kenyon et al [26] reported that an 8-hole LCP precontoured clavicle locking plate was used as an external fixator to achieve fracture site stability while the local infection was treated, a successful union was obtained 6 months later and the

Table 1: Summary of the characteristics of studies included (n=22).

Author	Published	Country	Study	Evidence	Inclusive population	Number	Gender	Mean Age	Role
	year		design	level			(male/female)	(year)	
Apivatthakakul	2007	Thailand	CR	IV	Open distal tibial fracture with bone defect	1	1/0	29	DEF
El-Desouky	2017	Egypt	CS	IV	Calcaneal fractures	30	24/6	37.9±5.7	DEF
H Huang	2013	China	CS	IV	Calcaneal fractures	12 (13fracture)	10/2	35	DEF
GZ Zhang	2012	China	CS	IV	Calcaneal fractures	25	25/0	37.2	DEF
Ebraheim	2014	American	CS	IV	Closed proximal tibial fractures	2	2/0	50.5	TEM
CH Ma	2017	China (Taiwan)	CS	IV	Open tibial fractures	52 (54fractures)	32/20	41	DEF
CH Ma	2017	China (Taiwan)	CS	IV	Segmental tibial fractures	25 (3 closed fractures)	15/10	38	TEM
ZF Mei	2014	China	CS	IV	Middle and distal tibial fractures	18 (12closed fractures)	11/7	53.5	DEF
XS Qiu	2013	China	CS	IV	Tibial fractures with compromised soft tissue envelop	12 (3 closed fractures)	9/3	50	DEF
Radha krishna	2017	India	CS	IV	Pediatric open tibial fractures	29	15/13	8.9±2.93	DEF
Tulner	2012	Netherlands	CS	IV	Infected non-union of the tibia	7	6/1	43	DEF: 3 TEM: 4
Woon	2010	Singapore	CR	IV	Open tibial fracture: 1	2	2/0	46	DEF: 1 TEM: 1
W Gang	2013	China	CS	IV	Open tibial fractures	36	21/15	42	DEF
JW Zhang	2015	China	CS	IV	Tibial proximal metaphyseal Fractures	35 (25 closed fractures)	26/9	42	DEF
JW Zhang	2016	China	CS	IV	Distal tibial fractures	28 (21closed fractures)	21/7	43	DEF
W Zhao	2014	China	CS	IV	Pediatric tibial fractures	8	6/2	7	DEF
Y Zhou	2015	China	CS	IV	Closed distal tibial fractures	23	16/7	39.5	DEF
H Lian	2015	China	CS	III	Closed tibial shaft fractures	25	16/9	34	DEF
Kenyon	2016	Ireland	CR	IV	Infected clavicle fracture	1	1/0	37	DEF
Kloen	2009	Netherland	CS	IV	Chronic posttraumatic infection	4	2/2	43	DEF: 3 TEM: 1
Sirisreetreerux	2013	Thailand	CR	IV	Gunshot injury with infected open clavicle fracture	1	1/0	20	DEF
C Xiao	2016	China	CS	IV	Infected nonunion of the humeral diaphysis	7	5/2	40.9	DEF

CR: Case Report; CS: Case Series; DEF: Definitive Fixation; TEM: Temporary Fixation.

Table 2: Summary of the clinical characteristics of studies included (n=22).

Author	Inclusive population	Mean follow-up Mean time to union		Union rate (%)	Function Outcome
		(month)	(week)		
Apivatthakal	Open distal tibial fracture with bone defect	-	40	100	Functional outcome was excellent with no pain, satisfactory ankle movement
El-Desouky	Calcaneal fractures	13.2	12	100	Bohler's angle was 10.57±4.8° preoperatively to 29.07±5.9° postoperatively AOFAS rating, the final score was 87.1±17.1(51 to 100); Excellent: 12, good: 11, fair: 5, poor: 2
H Huang	Calcaneal fractures	10	16	100	Bohler's angle was 11.19±5.69° preoperatively to 30.13±7.52° postoperatively Gissane' angle was 108.31±10.35° preoperatively to 118.99±8.94° postoperatively Maryland foot score system was 88.79±8.25; Excellent: 8, good: 3, fair: 2
Ebraheim	Closed proximal tibial fractures	-	-	50	One case: knee ROM was 140°; weight-bearing with no pain One case: weight-bearing
CH Ma	Open tibial fractures	38	34.5	100	Mean ROM: Knee (extension-flexion): 1° (0 -7°) to 141° (85°-145°); Ankle (dorsiflexion-plantar flexion): 8° (0 -20°) to 35° (0-50°); HSS score: 4 weeks/final: 85 (81-100)/94 AOFAS: 4 weeks/final:88 (80-100)/96 (90-100)(88-100);
CH Ma	Segmental tibial fractures	32	Proximal fracture: 23 Distal fracture: 27	100	Final mean ROM: Knee: 0-145°; Ankle: 0-35°; Functional outcomes*: Excellent: 21; Good: 4

ZF Mei	Middle and distal tibial fractures	11	-	100	Johner-Wruhs criteria: Excellent: 10; Good: 6; Fair: 2 Poor: 0
XS Qiu	Tibial fractures with compromised soft tissue envelop Proximal, distal and shaft fracture: 21.2, 23.5, 48.1, respectively	32	37.8	100	Final mean ROM: Knee: extension 0 to flexion 135° Ankle: dorsi flexion 12° to plantar flexion 32° Functional outcomes*: All were Excellent or Good
Radhakrishna	Pediatric open tibial fractures	13.5	11.5	100	All children regained full range of movement at the ankle and knee
Tulner	Infected non-union of the tibia	12.8	-	100	All patients were fully weight bearing with a well-healed tibia
Woon	Open tibial fracture: 1 Tibial plateau fracture with compartment syndrome: 1	-	8 and 13months	100	Full weight bearing with or without aid
W Gang	Open tibial fractures	15.2	23	100	ROM of Knee-At removing external fixation/ Last follow-up: 104.3°±21.1°/115.3°±13.3°; ROM of Ankle-At removing external fixation/ Last follow-up: 51.4°± 6.5°/ 55.0°±7.8°
JW Zhang	Tibial proximal metaphyseal Fractures	18	14	100	Mean HSS score 4 weeks/final: 91(85-100) and 98 (93 to 100); Mean AOFAS score 4 weeks/final: 94 (90 to 100) and 98 (95 to 100)
JW Zhang	Distal tibial fractures	16.2	16.7	100	Final AOFAS score: 93 (88-100)
W Zhao	Pediatric tibial fractures	12-Jun	3.9months	100	Johner-Wruhs criteria: excellent: 7; good: 1 Seven cases were visually normal after walking with stand; One case of anterior tibial tendon defect affected gait
Y Zhou	Closed distal tibial fractures	19.6	29.4	95.7	-
H Lian	Closed tibial shatt fractures	16.1	16.1	96	Johner-Wruhs criteria: Excellent:15; Good: 8; Fair: 1; Poor: 1 Excellent and good rate: 92%
Kenyon	Infected clavicle fracture	-	6 months	100	Full functional use of the limb Range of motion that was equal to the contralateral side
Kloen	Chronic posttraumatic infection:	-	-	100	-
Sirisreetreerx	Infected open clavicle fractures	-	8	100	Full shoulder range of motion
C Xiao	Infected nonunion of the humeral diaphysis	26.3	7.9	100	Mean shortening of the affected upper limb: 3cm; The mean ROM of the elbow was 1.4°extension and 131.4° flexion. The average DASH score of the involved limbs was 3.2 (range 0-13.4). All patients obtained excellent or good functional results

AOFAS: American Orthopedic Foot and Ankle Society; **AOFAS rating system:** points of 90 = excellent, 80 = good, 70 = fair, and, <70 = poor; **ROM:** range of motion; **HSS score:** The Hospital for Special Surgery (HHS) knee score; *: Functional results were based on five criteria: Presence of a limp; Stiffness of the knee or the ankle; **Pain;** Soft-tissue sympathetic dysfunction; Inability to perform previous activities of daily living. **Excellent result:** absence of all of the five outcomes; **Good result:** presence of one of the outcome criteria; **Fair result:** presence of two of the outcome criteria; **Poor result:** presence of three or more of the five criteria.

Table 3: Summary of the complications of studies included (n=22).

Author	Inclusive population	Nubmer	Complications
Apivatthakul	Open distal tibial fracture with bone defect	1	None
El-Desouky	Calcaneal fractures	30	Heel pain :10 (mal-union: 4; Superficial screw tract infection: 6)
H Huang	Calcaneal fractures	12 (13 fractures)	Superficial effusion: 1
GZ Zhang	Calcaneal fractures	25	Superficial wound necrosis: 2; Transient local posttraumatic osteoporosis: 5
Ebraheim	Closed proximal tibial fractures	2	Delayed union: 1
CH Ma	Open tibial fractures	52 (54 fracture)	Pin tract infection: 7; Malunion (>5°): 2; Shortening (>1 cm): 2; Screw loosening: 6 screws in 5 cases; Screw broken: 4 screws in 3 cases
CH Ma	Segmental tibial fractures	25 (3 closed fractures)	Pin track infection: 3; Delayed union: 3; Malunion (>5°): 2; Shortening (>1 cm): 2
ZF Mei	Middle and distal tibial fractures	18 (12 closed fractures)	Skin necrosis: 2; Pin infection: 1; Delayed union: 2
XS Qiu	Tibial fractures with compromised soft tissue envelop	12 (3 closed fractures)	Pin tract infection: 1
Radhakrishna	Pediatric open tibial fractures	29	Pin tract infection: 6
Tulner	Infected non-union of the tibia	7	None
Woon	Tibial fractures	2	Delayed union: 1
W Gang	Open tibial fractures	36	Superficial infection: 3; Deep infection: 1; Deep vein thrombosis: 5; Delayed union: 5
JW Zhang	Tibial proximal metaphyseal Fractures	35 (25 closed fractures)	Superficial effusion: 2
JW Zhang	Distal tibial fractures	28 (21closed fractures)	Superficial pin site effusion: 3
W Zhao	Pediatric tibial fractures	8	None

Y Zhou	Closed distal tibial fractures	23	Superficial screw-track infections: 2; Ununion: 1
H Lian	Closed tibial shaft fractures	25	Ununion: 1; Plating broken: 1; Pin infection: 1
Kenyon	Infected clavicle fracture	1	None
Kloen	Chronic posttraumatic infection	4	None
Sirisreerux	Infected open clavicle fractures	1	None
C Xiao	Infected nonunion of the humeral diaphysis	7	Pin tract infection: 1; Radial nerve injury: 1

patient had regained a shoulder range of motion that was equal to the contralateral side. Kloen et al [7] placed a 3.5-mm LCP as an external fixator to treat a patient with infected- nonunion clavicle fracture, the LCP was removed after 2 months when the wound had healed. The definitive internal fixation was performed then by using a LCP pelvic reconstruction plate combined with iliac crest bone graft. Two months later, the nonunion had healed, the patient reported no pain with nearly full function. Sirisreerux et al [23] present a gunshot injury with complex open clavicle fracture that was successfully treated with external fixation using a locking compression plate as definitive treatment. The patient showed radiographic union by eight weeks postoperatively with full shoulder range of motion. Kloen et al [7] also used LCP as an external fixation to treat three infected tibia and two of them were used as a definitive fixation, no significant screw tract infections or loosening were found. Tulner [25] and C Xiao et al [10] were used supercutaneous locking plate to treat infected non-union of the tibia (n=7) and the humeral diaphysis (n=7) respectively. They reported that all the patients gain union and had a satisfactory outcome (Table 2).

Fractures

Calcaneal fractures

Three [12-14] of the studies mentioned they utilized LCP as an external fixation for calcaneal fractures treatment with total of 67 patients (68 feet). The mean age and follow-up time was 53.80 years old and 20.97 months, respectively. All of the fractures were union and the average union time was 12.76 weeks. The mean Bohler's angle from these studies was 11.2° preoperatively (ranged from 10.57° to 12°) to 29.6° postoperatively (ranged from 29.07° to 30.13°) [12-14]. The mean Gissane' angle was 101.0° preoperatively (ranged from 87° to 108.31°) to 118.0° postoperatively (ranged from 116° to 118.99°) [13,14]. Two [12,14] of the studies reported AOFAS score to evaluate the functional outcome of ankle. The mean AOFAS score was 88.87 (ranged from 51 to 100). In H Huang's study [13], the final Maryland foot score system was 88.79±8.25, with 8 cases were excellent, three cases were good and 2 cases were fair.

Tibial fractures

Twelve studies [9,15-22,24,27,28] described that they used locked plate as an external fixator to treat the tibial fractures with 292 patients (294 limbs) and 117 of them were closed fractures. Two of these studies [27,28] used it as a temporary fixation. Radhakrishna [18] and W Zhao [21] placed the supercutaneous LCP for fixing pediatric tibial fractures (n=37). However, the function outcome measures reported in studies were different which makes comparison difficult. American Orthopaedic Foot and Ankle Society (AOFAS) ankle score was measured in three studies (115 patients with 117 limbs) [15,19,20], the mean final AOFAS score was 95.88. Two studies [15,19] measured

the Hospital for Special Surgery (HSS) knee scoring system to evaluate the function of the knee (87 patients with 89 fractures). The mean HSS knee score was 87 at 4 weeks postoperatively and 96 at final follow-up, which reflected the satisfactory of the knee joint. A total of three studies measured the Johner-Wruhs criteria [13,16,24], and the mean excellent and good rates were 92.16% (47/51). The functional criteria described by CH Ma et al [28] and XS Qiu et al [17] including five aspects: presence of a limp, stiffness of the knee or the ankle, pain, soft-tissue sympathetic dysfunction, and the inability to perform previous activities of daily living (Table 2). All patients in the two studies obtained the excellent and good results. Four studies [9,15,17,28] reported the knee and ankle's range of motion (n=125). The overall mean range of knee (extension-flexion) was 133.4° at final follow-up, and the overall mean range of ankle (dorsiflexion-plantar flexion) was 40.0° at final follow-up. All of the twelve studies reported the union cases [9,15-22,24,27,28]. Only 2 cases with ununion and 9 cases with delayed union were found in 292 patients, the pooled union rate was 96.23%. Ten of the studies showed the union time, and the mean union time was 23.18 weeks [9,15,17-22,24,28].

Complication

All of the clinical studies reported complications range from 0% to 40% [7-10,12-29]. No complication was found by Apivattha ka kul when he undertook the supercutaneous locking plate to treat the tibial defect [8]. Two cases were reported in 20 cases (one with pin tract infection and one with radial nerve injury), when the supercutaneous locking plates were used for treating chronic posttraumatic infection [10,23,25,26,29]. With regard to the 67 patients (68 feet) with calcaneal fractures, the most common complication was heel pain (10 cases) which caused by mal-union in 4 cases and superficial screw tract infection in 6 cases. Transient local posttraumatic osteoporosis was found in 5 cases, superficial wound necrosis in 2 cases and superficial effusion in one case [12-14]. The most common complication was the superficial pin-tract infection which accounted for 9.52% when the locking plate was used as an external fixation for tibial fractures (28 cases in 294 limbs). Delayed union rate was 3.74% (11 cases in 294 limbs). The remaining complications occurred with a frequency of 0.34% to 2.04% each and included deep infection; deep vein thrombosis; skin necrosis; ununion; plating broken; screw loosening; screw broken; shortening; and malunion.

Discussion

Kerkhoffs et al were the first to describe method for the fixation of fractures with external dynamic compression plate [30]. After that, Kloen et al [7] used a locked compression plate as external fixation for treating chronic posttraumatic problems. When the locking plate and screws are used, the stability of the fracture is not rely on the friction between the plate and the bone, but by the rigid connection between the plate and the locking of the screw head. Thus, the whole

components acting as one stable construct [31]. The principle of the LCP is similar to the external fixator, which is an angle-stabilising property. Therefore, the LCP can be used as an external fixation theoretically. Recently, a number of surgeons reported the application of supercutaneous locking plate fixation in orthopedics. The indication of this technique includes chronic posttraumatic infection [10,23,25,26,29], open or closed fractures [9,12-22,24,27,28], and even as an adjunct in distraction osteogenesis [8].

Only a few articles reported the biomedical characteristics of supercutaneous locking plate, unfortunately they were all tibial fractures models [15,32-34]. According to Kanchanomai et al's results, the partial weight bearing is possible for stable fractured tibia fixed by locking plate fixators, but to those patients who suffered from unstable tibial fractures, the partial weight bearing should be considered cautiously in the early phase of treatment. All LCP-tibial models were cyclically loaded beyond 500,000 cycles which simulated as approximately 6 months of healing, and no failure of LCP was observed. The biomechanical results of CH Maet al [15] exhibited although the axial stiffness of the external LCP group decreased by about 80% compared with that of the internal LCP group, but remained greater than that of the EF group. Moreover, the external LCP group had sufficient torsional stiffness compared with the internal LCP and EF groups. Thus, they inferred the locking plate offset at a distance of 6 cm from the bone surface is biomechanically feasible as a definitive treatment of tibial metaphyseal fracture. These studies confirmed the biomechanical safety of external LCP in treating the tibial fracture. Due to the heterogeneity of biomechanical studies, we can only conclude that external locked plate shows inferior structural stiffness than internal locked plate in treating the tibial fracture models. However, we only found one case with plating broken, five cases with 6 screws loosening and 3 cases with 4 screws broken in 382 cases combated in 22 inclusive clinical studies. In addition, only 9 cases with delayed union and 2 cases with ununion were found in 382 cases and the union rate was 97.12%. The high union rate somehow showed the biomedical stability of the external locking plate.

Several authors stated this technique has many benefits [7,17,24]:

1. It could minimize the damage to the soft tissues, decrease the complications after immediate open reduction and internal fixation of fractures.
 2. Patients can easily conceal the properties under regular clothing, it may be more acceptable to patients as the low-profile plates overcome the shortcomings of standard external fixators.
 3. Utilizing the locking plate as a definitive external fixator does not need to across the joint, which makes early function exercise possible.
 4. The external plate can be easily removed in the clinic without anesthesia, which could reduce the financial burden of patients.
- Woon [29] presented that there are other theoretical advantages should be tested experimentally. First, axial micro motion may reduce stress-shielding of the fracture site and load-sharing during weight bearing may stimulate the callus formation until bony union. Second, "controlled destiffening" by removing screws closest to the fracture site is possible, allowing some measure of control to the load-sharing process. Nevertheless, we should note that supercutaneous locking plate also have the disadvantage [7, 17]:
1. The plate as an external fixator can be harder to manipulate and adjust because highly accurate anatomical reduction of the fracture site should be achieved;
 2. Compared with the standard external fixator, the costs of locked plate is much higher and the plates and screws cannot be reused.

As far as we are concerned, this is the first systematic review focus on the application of supercutaneous locking plate fixation in orthopedics, the results showed it is an effective and safe method to manage the orthopedic disorders such as chronic posttraumatic infection, fractures and even as an auxiliary equipment in distraction osteogenesis. However, there are several limitations of this review: Firstly, we cannot carry out the meta-analysis due to the heterogeneity of individual studies; Secondly, high-quality studies were insufficient because most reviewed articles are case series and case reports and more than half of the inclusive studies in this review written by Chinese (2 from Taiwan) which may cause selection bias. Therefore, we suggest that powered randomized controlled trials comparing well-matched patient groups with long-term follow-up are required to limit systematic error and enhance external validity. Specific outcome measures should include union, functional assessment, complications and cost-benefit analysis.

Conclusion

Based on the clinical studies, locked plating as an external fixator to manage orthopedic disorders can be considered as a safe and successful procedure. However, as yet, there is unconvincing evidence that it is superior to standard techniques with regards to clinical and functional outcomes. Thus, more and well-designed studies about this technique should be carried out further.

References

1. Helm M. [Reliability of emergency medical field triage: Exemplified by traffic accident victims]. *Anaesthesist*. 2013; 62: 973-980.
2. Miller DL, T Goswami. A review of locking compression plate biomechanics and their advantages as internal fixators in fracture healing. *Clin Biomech (Bristol, Avon)*. 2007; 22: 1049-1062.
3. Dillin L, P Slabaugh. Delayed wound healing, infection, and nonunion following open reduction and internal fixation of tibial plafond fractures. *J Trauma*. 1986; 26: 1116-1119.
4. Hedin H. Surgical treatment of femoral fractures in children. Comparison between external fixation and elastic intramedullary nails: a review. *Acta Orthop Scand*. 2004; 7: 231-240.
5. Niemeyer P, NP Sudkamp. Principles and clinical application of the locking compression plate (LCP). *Acta Chir Orthop Traumatol Cech*. 2006; 73: 221-228.
6. Greiwe RM, MT Archdeacon, Locking plate technology: current concepts. *J Knee Surg*. 2007; 20: 50-55.
7. Kloen P. Supercutaneous plating: Use of a locking compression plate as an external fixator. *Journal of Orthopaedic Trauma*. 2009; 23: 72-75.
8. Apivatthakakul T, K Sananpanich. The locking compression plate as an external fixator for bone transport in the treatment of a large distal tibial defect: A case report. *Injury*. 2007; 38: 1318-1325.
9. Wu G. [Comparison study on locking compress plate external fixator and standard external fixator for treatment of tibial open fractures]. *Zhongguo xiu fu chong jian wai ke za zhi = Zhongguo xiu fu chongjian waik e zazhi = Chinese journal of reparative and reconstructive surgery*. 2013; 27: 1291-1295.
10. Xiao C. A locking compression plate as an external fixator for treating infected nonunion of the humeral diaphysis. *BMC Surgery*. 2016; 16: 53.
11. Panic N. Evaluation of the endorsement of the preferred reporting items for systematic reviews and meta-analysis (PRISMA) statement on the quality of published systematic review and meta-analyses. *PLoS One*. 2013; 8: e83138.
12. El-Desouky II, W Abu Senna. The outcome of super-cutaneous locked plate fixation with percutaneous reduction of displaced intra-articular calcaneal fractures. *Injury*. 2017; 48: 525-530.

13. Huang H. [Treatment of intra-articular calcaneal fractures by minimally invasive through the sinus tarsi approach and external fixation with calcaneal locking plates]. *Zhongguo Gu Shang*. 2013; 26: 893-896.
14. Zhang G, X Jiang, M Wang. External fixation with supercutaneous calcaneal locking plate for displaced intra-articular calcaneal fractures. *Foot & Ankle International*. 2012; 33: 1113-1118.
15. Ma CH. Metaphyseal locking plate as an external fixator for open tibial fracture: Clinical outcomes and biomechanical assessment. *Injury*. 2017; 48: 501-505.
16. Mei ZF. [Locking plate external fixator for the treatment of middle and distal tibial fractures]. *Zhongguo gu shang = China journal of orthopaedics and traumatology*. 2014; 27: 458-460.
17. Qiu XS. Locking plate as a definitive external fixator for treating tibial fractures with compromised soft tissue envelop. *Archives of Orthopaedic and Trauma Surgery*. 2014; 134: 383-388.
18. Radhakrishna VN, V Madhuri. Management of pediatric open tibia fractures with supracutaneous locked plates. *J Pediatr Orthop B*. 2017.
19. Zhang J. External fixation using femoral less invasive stabilization system plate in tibial proximal metaphyseal fracture. *CiOS Clinics in Orthopedic Surgery*. 2015; 7: 8-14.
20. Zhang JW. Distal tibial fracture: An ideal indication for external fixation using locking plate. *Chinese Journal of Traumatology*. 2016; 19: 104-108.
21. Zhao W. [Locking plate percutaneous external fixation for the treatment of pediatric tibial fractures]. *Zhongguo Gushang*. 2014; 27: 597-600.
22. Lian H, J Huang. [Effectiveness Comparison of Different Operative Methods in Treatment of Closed Fracture of Tibial Shaft]. *Chung-Kuo Hsiu Fu Chung Chien Wai Ko Tsa Chih/Chinese Journal of Reparative & Reconstructive Surgery*. 2015; 29: 1067-1071.
23. Sirisreetreerux N. Using a reconstruction locking compression plate as external fixator in infected open clavicle fracture. *Orthopedic Reviews*. 2013; 5: 52-55.
24. Zhou Y. Locking compression plate as an external fixator in the treatment of closed distal tibial fractures. *International Orthopaedics*. 2015; 39: 2227-2237.
25. Tulner SAF, SD Strackee, P Kloen. Metaphyseal locking compression plate as an external fixator for the distal tibia. *International Orthopaedics*. 2012; 36: 1923-1927.
26. Kenyon RM. Locking plate external fixation and negative pressure wound therapy for treatment of a primary infection in a closed clavicle fracture. *BMJ Case Rep*. 2016.
27. Ebraheim NA. Staged treatment of proximal tibial fracture using external locking compression plate. *Orthopaedic Audio-Synopsis Continuing Medical Education [Sound Recording]*. 2014; 6: 154-157.
28. Ma CH. Using external and internal locking plates in a two-stage protocol for treatment of segmental tibial fractures. *Journal of Trauma - Injury, Infection and Critical Care*. 2011. 71: 614-619.
29. Woon CY, MK Wong, TS Howe. LCP external fixation--external application of an internal fixator: two cases and a review of the literature. *Journal of Orthopaedic Surgery*. 2010; 5: 19.
30. Kerkhoffs GM. External fixation with standard AO-plates: technique, indications, and results in 31 cases. *J Orthop Trauma*. 2003; 17: 61-64.
31. Wagner M. General principles for the clinical use of the LCP. *Injury*. 2003. 34: B31-42.
32. Kanchanomai C, V Phiphombongkol. Biomechanical evaluation of fractured tibia externally fixed with an LCP. *Journal of Applied Biomechanics*. 2012; 28: 587-592.
33. Liu W. Stiffness of the locking compression plate as an external fixator for treating distal tibial fractures: a biomechanics study. *BMC Musculoskeletal Disorders*. 2017; 18: 1-6.
34. Zhang J. External fixation using locking plate in distal tibial fracture: a finite element analysis. *European journal of orthopaedic surgery & traumatologie*. 2015; 25: 1099-1104.